



Left Hepatic Duct Stones Diagnosis and Treatment: Clinical Case

Castro-Vargas JM^{1*}, Manjarrez Tah AG², Alejandro Gudino S³, Arredondo GP⁴, Rios LU⁵, Silverio VI¹ and Ma Ferretiz DIAM⁶

¹Graduate program at the Faculty of Medicine, Autonomous University of Yucatan and General Surgery Residents, General Surgery Service of the General Hospital of Cancun, Q. Roo, Mexico

²Medical Director, General Surgery and Advanced Laparoscopy Specialist at San Lucas Medical Center, Mexico

³General Surgeon at San Lucas Medical Center, Mexico

⁴General Surgeon and Endoscopist, Playa Del Carmen, Q. Roo, Mexico

⁵Rheumatologist and Internist, Research Department, Playa Del Carmen General Hospital, Q. Roo, Mexico

⁶General Surgeons, Department of Surgery, CanCun General Hospital, Q. Roo, Mexico

*Corresponding author: Castro-Vargas JM, Graduate program at the Faculty of Medicine, Autonomous University of Yucatan and General Surgery Residents, General Surgery Service of the General Hospital of Cancun, Q. Roo, Mexico; E-mail: jcastro9422@gmail.com

Abstract

Introduction: Hepatolithiasis characterized by the development of pigmented stones, composed of calcium bilirubinate and, to a lesser extent, cholesterol, in the intrahepatic bile ducts before their confluence with the common hepatic duct, regardless of the coexistence of gallstones in the common bile duct or gallbladder.

Clinical case: A 40-year-old male presented with abdominal pain of five months' duration, characterized by epigastric pain and dyspepsia. Jaundice, nausea, pruritus, choluria, and acholia were also present. An ultrasound revealing a gallbladder measuring 54x32x29 mm with a 3.2 mm wall. Multiple hyperechoic images projecting a posterior acoustic shadow, with a stone measuring 19.6 mm. There was no dilation of the intrahepatic bile ducts. Abnormal liver function tests were performed. ERCP revealing a stone measuring 15 mm in diameter at the common hepatic duct. It was impossible to extract the stone with papilla dilation, so the decision to place a 10 Fr plastic stent, and bile duct exploration as a decisive therapeutic method was recommended. Initiated laparoscopic cholecystectomy, a catheter was introduced into the cystic duct, and intraoperative cholangiography was performed, revealing a filling defect at the left hepatic duct, as well as multiple distal stones and a variable double right hepatic duct.

Discussion: Treatment of hepatolithiasis consists of stone extraction plus adjuvant drug therapy. Cholangitis usually coexists with hepatolithiasis; therefore, antibiotic therapy is necessary. For nonsurgical stone removal, PTCL or ERCP are used. Although a noninvasive approach is a promising treatment, the recurrence of hepatolithiasis is 20%. When hepatolithiasis coexists with bile duct strictures, which occurs in 40% of cases, since in these patients after PTCL or ERCP, the recurrence rate reaches up to 51%.

Keywords: Left hepatic duct hepatolithiasis; Biliary tract exploration; Cholangiography; Kehr tube

Introduction

The disease was described in Hong Kong in 1930 and is endemic to East and Southeast Asia, where its prevalence has reached 30%. For these reasons, it has also been called "oriental

cholangiohepatitis", "oriental cholangitis" or "Hong Kong disease" [1,2]. The incidence of hepatolithiasis varies even within Asian countries, with Taiwan historically having the highest relative prevalence. Glenn and Moody [3], reported in 1961 that patients of Asian descent living in the United States had an

Received date: 17 June 2025; Accepted date: 29 June 2025; Published date: 07 July 2025

Citation: Castro-Vargas JM, Manjarrez Tah AG, Alejandro Gudino S, Arredondo GP, Rios LU, Silverio VI, et al. (2025) Left Hepatic Duct Stones Diagnosis and Treatment: Clinical Case. SunText Rev Case Rep Image 6(3): 159.

DOI: <https://doi.org/10.51737/2766-4589.2025.159>

Copyright: © 2025 Castro-Vargas JM, et al. This is an open-access article distributed under the terms of the Creative Commons Attribution License, which permits unrestricted use, distribution, and reproduction in any medium, provided the original author and source are credited.

SUNTEXT REVIEWS

incidence of hepatolithiasis like that of the general American population, suggesting that the pathogenesis of the disease is primarily related to environmental factors, rather than genetic and ethnic factors. This reinforces the theory that improved living standards and a change in dietary habits significantly influences the decrease in incidence.

Clinical Case

A 40-year-old male presented with abdominal pain of five months' duration, characterized by epigastric pain and dyspepsia. Jaundice, nausea, pruritus, choloria, and acholia were also present. An ultrasound of the liver and bile duct showing a gallbladder measuring 54x32x29 mm with a 3.2 mm wall. Multiple hyperechoic images projected posterior acoustic shadowing, and the largest stone was 19.6 mm. There was no dilation of the intrahepatic bile ducts. The common bile duct was 1.9 mm, and the portal vein was 11 mm. Alterations in liver function tests included: BT 17.20 mg/dl, BD 12.20 mg/dl, and BI 5.0 mg/dl, AST: 87.6 mg/dl, ALT: 70.6 mg/dl, GGT: 83.5 mg/dl, and FA: 227.0 mg/dl. Since the ultrasound study did not show any evidence of obstruction of the intra- or extrahepatic bile duct, ERCP was indicated, observing a stone measuring 15 mm in diameter at the level of the common hepatic duct, a distal bile duct of normal diameter, impossibility of extracting the stone with papilla dilation, so it was decided to place a 10 Fr plastic stent, recommending exploration of the bile ducts as a resolving therapeutic method.

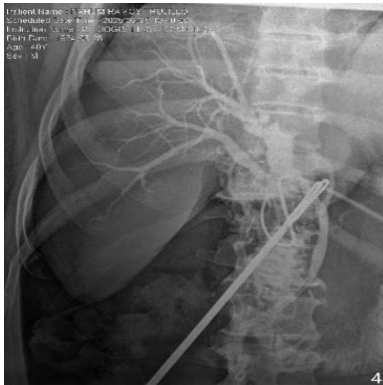

Figure 1: A variable of double right hepatic duct.

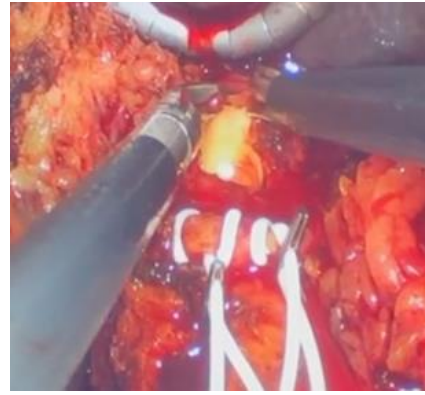

Figure 2: The left hepatic duct and is removed a 1.5 cm stone.

A laparoscopic cholecystectomy was initiated, revealing a Parkland V type gallbladder, a catheter was introduced into the cystic duct and an intraoperative cholangiography was performed, showing a filling defect at the level of the left hepatic duct, as well as multiple distal stones and a variable of double right hepatic duct (Figure 1). It is irrigated with saline solution, seeing spontaneous discharge of two stones < 5 mm, a flexible ureteroscope is introduced. At the approach site of the left hepatic duct with passage through the common bile duct to the duodenum without the presence of stones, a 12 Fr T-tube is placed, placing three stitches with 4-0 Vicryl. Saline solutions are instilled and hermeticity is checked, a new cholangiography is taken with a normal appearance (Figure 2-5).

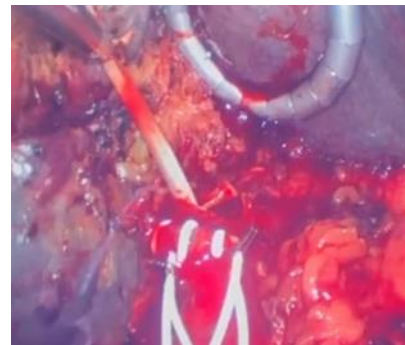


Figure 3: Prosthesis is shown and removed.



Figure 4: It is irrigated with saline solution, seeing spontaneous discharge of two stones < 5 mm, a flexible ureteroscope is introduced.

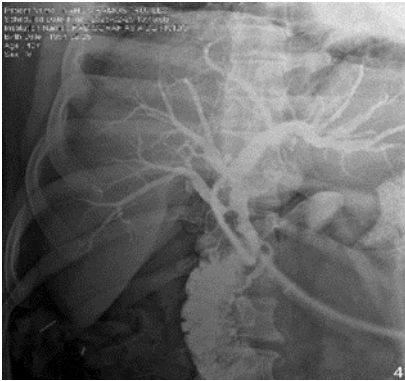


Figure 5: A new cholangiography is taken with a normal appearance.

Observing adequate passage of the contrast medium throughout the entire length of the biliary tract. The gallbladder is removed, a Penrose drain is placed over the Winslow hiatus, and the cavity is lavage, completing the surgical procedure with the resolution of the hepatolithiasis of the left hepatic duct.

Discussion

Cholelithiasis occurs in 5 to 10% of patients with gallstones and up to 18% of patients with gallstone pancreatitis. An estimated 21 to 34% of stones migrate spontaneously from the bile duct, and up to 25 to 36% are at risk of causing pancreatitis or cholangitis if obstructed. Treatment algorithms have been considered, including endoscopic retrograde cholangiopancreatography (ERCP) before cholecystectomy, intraoperative ERCP, and postoperative ERCP. However, 5 to 10% of these procedures may fail due to difficult access or inability to remove the stones. Stones considered difficult include those larger than 15 mm that cannot be captured in a basket, stones located in the intrahepatic biliary tract, stones associated with chronic biliary tract stricture, stones present in patients undergoing surgeries that modify the continuity of the proximal digestive tract (Billroth II gastrectomy or gastric bypass), and stones in patients with Mirizzi syndrome. These conditions drastically reduce the possibility of minimally invasive therapies. For example, residual stones have been reported in 5 to 14% of cases treated with laparoscopic biliary tract exploration [4-7]. Patients with hepatolithiasis often have concomitant extrahepatic gallstones. Therefore, in these cases, biliary exploration and stone extraction. Conventional choledochotomy requires dissection of the common bile duct; however, choledochotomy can be easily completed through the common bile duct stump [7].

Li R, [8] assert that biliary exploration through the left bile duct (LHD) stump can be safely performed in left-sided hepatolithiasis. Furthermore, the LHD approach was associated with comparable intraoperative outcomes and shorter postoperative hospitalization compared with the CBD approach,

and did not increase the incidence of stone recurrence. Therefore, hepatolithiasis refers to primary stones found above the confluence of the left and right hepatic ducts, and its main part is brown bile pigment stones. Hepatolithiasis is a disease with regional characteristics. Its incidence in Asia is higher than in Europe and America. In recent years, Japanese literature has reported a downward annual incidence of hepatolithiasis, but the outlook in China is still not optimistic, where the incidence in the population ranges between 2 and 25%. According to the literature, the incidence of intrahepatic cholangiocarcinoma in patients with hepatolithiasis is 1 to 23%, and that of liver cirrhosis in patients with hepatolithiasis is 4 to 14%. Therefore, early diagnosis of hepatolithiasis and proper treatment methods for intervention are useful in reducing the incidence of complications, improving the prognosis, and improving the median survival of patients. Currently, there is no exact explanation for the etiology of hepatolithiasis. National and international studies suggest that it may be related to lifestyle, biliary bacterial infection, biliary parasite infection (*Clonorchis sinensis*), biliary anatomical variation, genetic mutation, and abnormal gene expression, among others [9]. Treatment of hepatolithiasis consists of stone extraction plus adjuvant drug therapy. Cholangitis usually coexists with hepatolithiasis; therefore, antibiotic therapy is necessary. For nonsurgical stone extraction, PTCL or ERCP is used. Although a noninvasive approach is a promising treatment, the recurrence of hepatolithiasis is 20% and is not showed in all cases. For example, when hepatolithiasis coexists with bile duct strictures, which occurs in 40% of cases, the recurrence rate in these patients after PTCL or ERCP reaches 51%. In contrast, the recurrence rate of hepatolithiasis after surgical treatment ranges from 6% to 14%. In 93% of surgical cases, no residual stones are still, and when the surgical procedure is combined with the noninvasive method, the percentage of stone-free patient's increases to 96%.

On the other hand, treatment has evolved, and a conservative approach is trying to increase the use of endoscopic techniques and decrease the number of hepatectomies. A 55-year-old male patient with a history of multiple sclerosis was clinically asymptomatic but with elevated transaminase levels. Ultrasound revealed hepatic steatosis with dilation of the intrahepatic bile duct, with multiple hyperechoic images seen within the bile duct. An ERCP was performed, which ruled out choledocholithiasis. A CT scan confirmed marked dilation of the intrahepatic bile duct, on the right side. Lithiasis images were seen in the branches of both lobes and in the proximal area of the common hepatic duct, associated with periportal lymphadenopathy. Stones were extracted from both proximal bile ducts using an endoscopic technique; a flexible cystoscope was used, and stones were extracted from peripheral biliary branches, some of them being fragmented with a Holmium laser. In this case, the presence of



SUNTEXT REVIEWS

bilateral lithiasis of different sizes in main and peripheral branches of the biliary tree was observed, so hepatectomy should be avoided, extracting the largest and most accessible stones manually, and leaving the smallest and peripheral ones for destruction with the Holmium laser with a satisfactory combined surgical result. Although the indications continue to be varied, most author's use this technique when there are single stones larger than 2 cm, multiple, bilateral, impacted, or difficult to find, having previously performed ERCP without success [10]. On the other hand, there are various studies that try to help prevent the formation of stones in the body, which include studies about alcohol intake, the usefulness of physical exercise and changes in diet, the sitting position in order to prevent this serious disease that although it is not very common, it is disabling and fatal [11-15].

Conclusion

Despite best efforts, none of the existing therapeutic approaches can guarantee complete clearance, and post-treatment follow-up is necessary to address residual or recurrent stones. Recurrent stones and cholangitis occur at a frequency of 9 to 16% after surgery and 30 to 40% after percutaneous or endoscopic lithotomy. Despite advances in different treatment methods for hepatolithiasis, significant challenges to success include intrahepatic biliary strictures, impacted stones, and inaccessible peripheral stones.

References

1. Motta RV, Saffioti F, Mavroeidis VK. Hepatolithiasis: Epidemiology, presentation, classification, and management of complex diseases. *WJ Gastroenterol.* 2024; 30: 1836-1850.
2. Digby KH. Common-duct stones of liver origin. *Brit J Surg.* 1930; 17: 578-591.
3. Glenn F, Moody FG. Intrahepatic calculi. *Ann Surg.* 1961; 153: 711-724.
4. Amaro EXS, Villanueva HA, Ortiz AM, Valdivieso EP. Massive lithiasis of the intra- and extrahepatic biliary tract. Report on two cases. *Rev Fac Med.* 2023; 66: 35-37.
5. Jindal S, Bagwan AI, Rathinasamy RRP, Chidambaranathan S, OLN. Hepatolithiasis: a retrospective analysis of surgical management options in a tertiary care center in Southern India. *Cureus.* 2022; 14: e27797.
6. Cuendis-Velazquez A, Rojano-Rodriguez ME, Morales-Chavez CE, Angulo-Rocha AG, Fernandez-Castro E, Aguirre-Olmedo I, et al. The usefulness of intraoperative choledochoscopy in the treatment of difficult biliary stones. *Rev Gastroenterol Mex.* 2014; 79: 22-27.
7. Zhou Y, Zha W, Wu X, Fan R, Zhang B, Xu Y, et al. Biliary exploration via the left hepatic duct orifice versus the common bile duct in left-sided hepatolithiasis patients with a history of biliary tract surgery. *Med.* 2018; 97: e9643.
8. Shan B, Tian K, Zhang X, Xie X. Biliary tract exploration via left hepatic duct stump versus the common bile duct incision in left-sided hepatolithiasis: a meta-analysis. *ANZ J Surg.* 2021; 91.
9. Ye Y, Li P, Wu Q, Yang S, Zhuang B, Cao Y, et al. Evolution of surgical treatment for hepatolithiasis. *WJ Gastrointestinal Surg.* 2024; 16: 3666-3674.
10. Roldan Vasquez E, Jarrin Estupinan X, Vasconez Hatt O, Serpa Larrea F, Roldan Crespo J. Left-sided hepatolithiasis managed with hepatectomy: A case report. *Rev Med Vozandes.* 2020; 31: 21-28.
11. Cha BH, Jang MJ, Lee SH. Alcohol consumption can reduce the risk of gallstone disease: a systematic review with a dose-response meta-analysis of case-control and cohort studies. *Gut Liver.* 2019; 13: 114-131.
12. Tejera Hernandez AA, Cabrera Garcia ME, Navarro Medina P, Garcia Plaza G, Larrea Olea FJ, Hernandez-Hernandez JR. Hepatolithiasis. Endoscopic surgical approach using holmium laser for its treatment. *Gastroenterol Hepatol.* 2017; 40: 16-33.
13. Chang CM, Chiu THT, Chang CC, Lin MN, Lin CL. Plant-based diet, cholesterol, and risk of gallstone disease: a prospective study. *Nutrients.* 2019; 11.
14. Ryu S, Chang Y, Kim YS, Kim HJ. Prolonged sitting increases the risk of gallstone disease regardless of physical activity: a cohort study. *Scand J Gastroenterol.* 2018; 53: 864-869.
15. Zhang YP, Zhao YL, Sun YL, Zhu RT, Wang WJ, Li J. Physical Activity, and the Risk of Gallstone Disease: A Systematic Review and Meta-analysis. *J Clin Gastroenterol.* 2017; 51: 857-868.