



# Pediatric Endourology: A Single Center Experience

Omodu OJ\* and Emudianughe PO

*Colworths medical center, Port Harcourt, Rivers State, Nigeria*

\*Corresponding author: Omodu OJ, Colworths medical center, Port Harcourt, Rivers State, Nigeria; E-mail: [ovundaomodu@gmail.com](mailto:ovundaomodu@gmail.com)

## Abstract

**Background:** Endourology has relatively matured in the area of adult disease conditions but has remained largely under-developed with respect to paediatric endourology. This is mainly due to our resource-poor environment in developing countries. Cystoscopy is the endoscopic visualization of both the urethra and bladder while ureteroscopy is the visualization of the ureter. Both of these procedures are important in making a diagnosis or effecting a treatment.

**Aim:** The aim of this study is to demonstrate our experience in paediatric endourology so adequate diagnoses as well as further treatment can be made.

**Patient and Methods:** This paper highlights a prospective study of cystoscopies in paediatric patients carried out in Colworths Medical Centre between November 2015 and November 2021. Information obtained and analysed include age, diagnosis, procedure and complications. All cystoscopies were done with slight sedation of the patients using a combination of pentazocine and diazepam. A cystoscope size of 7fr, 8.5fr and 10fr were used depending on the size of the external meatus.

**Results:** During the period of study, 34 babies ean age of 8.7 were diagnosed with bladder outlet obstruction. 17 [50%] babies had posterior urethral valve, 5 [14.7%] babies had a direct vision internal urethrotomy [DVIU], 3 [8.8%] babies had diagnostic cystoscopy, 4 [11.8%] babies had cystolithotripsy, 2 [5.9%] babies had ureterolithotripsy, and 3 [8.8%] babies had double J [DJ] insertion. There were trabeculations, diverticular and some bladder calculi seen during the cystoscopy. 2 [5.9%] babies had post-cystoscopic urinary tract infection.

**Conclusion:** Cystoscopic evaluation in children with bladder outlet obstruction is key for adequate diagnosis and prompt treatment.

**Keywords:** Cystoscope; Paediatric; Endourology

## Introduction

Endourologic surgery involves the use of specialized instruments that can enter the urinary tract via the urethra eliminating the need for incisions [1]. Endourology has relatively matured in the area of adult disease conditions, however, paediatric endourology has remained largely under-developed in developing countries due to our resource-poor environment. Paediatric endourologic procedures include but not limited to; Deflux injection for vesicoureteral reflux, bladder outlet injection for urinary incontinence, removal of stones from the kidney, ureter or bladder, treatment of posterior urethral valve, endoscopic management of ureterocele, ureteroscopy, endopyelotomy for

obstructed kidneys [2]. As with any surgical procedure, the risk of infection is present. A variety of antimicrobial prophylaxis strategies to reduce the risk of urinary tract infection (UTI) after flexible cystoscopy have been described [3,4]. The primary objective of this study is to illustrate our experience in paediatric endourology in making adequate diagnosis and further treatment achieved.

## Patient and Methods

This paper highlights a prospective study of cystoscopies in paediatric patients carried out in Colworths Medical Centre between November 2015 and November 2021. Information

**Received date:** 26 November 2024; **Accepted date:** 05 December 2024; **Published date:** 13 December 2024

**Citation:** Omodu OJ, Emudianughe PO (2024) Assessment and Identification of Medicinal Plants at Habro, Gemechis and Hawi Gudina Districts in East Oromia Region, Ethiopia. SunText Rev Med Clin Res 5(2): 201.

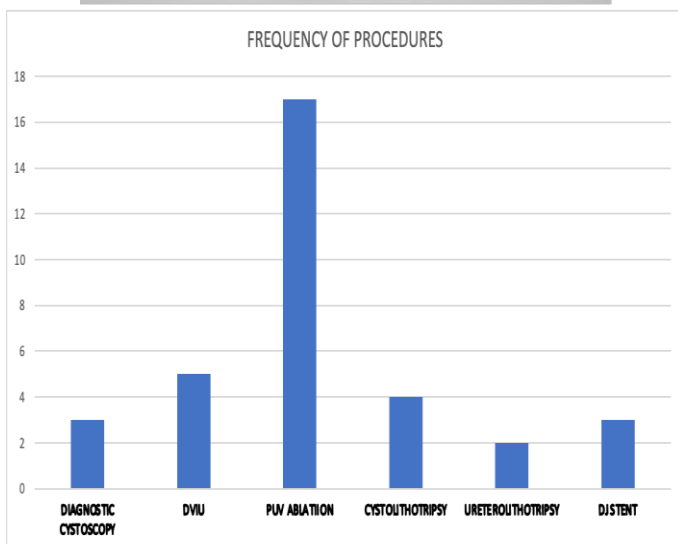
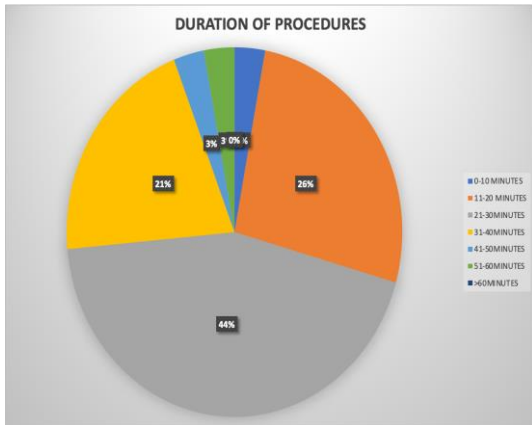
**DOI:** <https://doi.org/10.51737/2766-4813.2024.101>

**Copyright:** © 2024 Omodu OJ S, et al. This is an open-access article distributed under the terms of the Creative Commons Attribution License, which permits unrestricted use, distribution, and reproduction in any medium, provided the original author and source are credited.

obtained and analysed include age, diagnosis, procedure and complications. All cystoscopies were done with slight sedation of the patients using a combination of pentazocine and diazepam. A cystoscope size of 7fr, 8.5fr and 10fr were used depending on the size of the external meatus.

### Discussion

In 1806 a German army doctor, Philip Bozzini created the first device to see inside a human body. He called it Lichtleiter [5]. A surgeon may view inside a bodily cavity using the device's flame and angled mirrors. It was designed to view the pharynx initially, but was later modified to view the penis and urethra. This served as the impetus for additional endoscopic equipment exploration and advancement. In 1878, Maximilian Carl-Friedrich Nitze and Joseph Leiter created the first cystoscope that actually worked. Cystoscopy in children is safe, achievable and rational irrespective of the sex and age, and most times is the requisite for accurate diagnosis and treatment [6].



Once indicated, it should not be neglected. A cystoscopy will be mandatory in endoscopic therapy or when operative interventions are planned [5,6]. Prenatal laser ablation of the PUV under cystoscopy may prevent renal function deterioration thus

improving postnatal outcome. In addition, the use of foetal cystoscopy in the prenatal diagnosis to specifically differentiate between PUV and urethral atresia has also been demonstrated recently by Ruano et al [7]. Fetal cystoscopy has been described as an alternative option to vesicoamniotic shunting (VAS) by avoiding amnioinfusion and providing an etiological diagnosis for the obstruction prior to prenatal management [8]. The study revealed the duration and frequency of the procedure as seen in the pie and bar charts. Overall, within an average of 30 minutes, the procedure was completed with favourable outcomes. About 44% of endoscopic surgeries took about 21-30minutes although in few cases, it could exceed an hour. On the other hand, the bar chart illustrates how often endoscopic procedures were carried out. PUV ablation was the most common procedure done with a total of 17 babies, followed by DVIU [5 babies], cystolithotripsy [4 babies], djstent [3 babies], diagnostic cystoscopy [3 babies] and uretolithotripsy [2 babies] being the least performed.

### Conclusion

Following the results of our study, we have been able to evaluate the extent of endourological procedures performed in our centre. From the results posterior urethral valve ablation was the most frequently done procedure and there was no recorded mortality in all the procedures. Cystoscopic evaluation in children with bladder outlet obstruction is key for adequate diagnosis and prompt treatment.

### References

- Kim C, Docimo SG. Use of laparoscopy in paediatric urology. *Rev Urol.* 2005; 7: 215-223
- Dalia G, Paola M, Piergiorgio G. Instrumentation for minimally invasive surgery in paediatric urology. *Translational Pediatrics.* 2016; 5: 186-204.
- Bratzler DW, Dellinger EP, Olsen KM, Auwaeter PG, Bolon MK, Fish DN, et al. Clinical practice guidelines for antimicrobial prophylaxis in surgery. *Surg Infect (Larchmt).* 2013; 14: 73-156.
- Bhanot N, Sahud AG, Sepkowitz D. Best practice policy statement on urologic surgery antimicrobial prophylaxis. *Urology.* 2009; 74: 236-237.
- Ramai D, Zakhia K, Etienne D, Reddy M. Philipp Bozzini. The earliest description of endoscopy. *J Medical Biography.* 2018; 26:137-141.
- Bickeboller R, Jonas D. The indication for cystoscopy in children. *Wiener Medizinische Wochenschrift.* 1997; 147: 490-491.
- Ruano R, Duarte S, Bunduki V, Giron AM, Srougi M, Zugaib M. Fetal cystoscopy for severe lower urinary tract obstruction initial experience of a single center. *Prenatal Diagnosis.* 2010; 30: 30-39.
- Welsh A, Agarwal S, Kumar S, Smith RP, Fisk NM. Fetal cystoscopy in the management of fetal obstructive uropathy: experience in a single European centre. *Prenatal Diagnosis.* 2003; 23: 1033-1041.