



## A Rare Case of Unintentional Victim of Brawl with Frontal Bone Injury Cause of Stray Arrow

Syahputra N and Petrus A\*

Faculty of Medicine, Department of Forensics and Medicolegal, University of North Sumatra, Indonesia

\*Corresponding author: Petrus A, Faculty of Medicine, Department of Forensics and Medicolegal, University of North Sumatra, Indonesia, Tel: +62 61 8211633; E-mail: [asanpetrus95@gmail.com](mailto:asanpetrus95@gmail.com)

### Abstract

**Background:** Frontal bone injuries accounts for 5%-15% of maxillofacial injuries; 66% of patients with frontal sinus injuries have associated maxillofacial fractures. When a patient presents with varying degrees and forms of injury, the physician and healthcare facility provide needed medical attention. Injury can lead to an act of persecution which can endanger the safety of the lives of the public, so this action is subject to a criminal act based on the Criminal Code in Indonesia Article 351.

**Objectives:** To report a rare case of unintentional victim of brawl with frontal bone injury cause of stray arrow.

**Case Illustration:** A 19 years old male with an arrow in his forehead was taken to emergency room at Haji Adam Malik Hospital Medan on 26 December 2022.

**Discussion:** Based on the wound qualification the injury sustained as moderate degree injury which prevent the victim to carrying out a job, position or temporary livelihood. But, there was no further judicial process in this case due to patient consent.

**Conclusion:** A 19 years old male with an arrow in his forehead was taken to emergency room at Haji Adam Malik Hospital Medan on 26 December 2022. This case was rare since the arrow was unintentionally hit the victim and patient came to hospital with full consciousness. Patient referred to neurosurgery department of Haji Adam Malik Hospital Medan and there was no further judicial process due to patient consent.

**Keywords:** Brawl victim; Frontal bone injury; Moderate degree injury; Penetrating trauma; Stray arrow

### Introduction

Frontal bone injuries are predominantly caused by high-velocity injuries such as motor vehicle accidents, assaults, and sporting events. It accounts for 5%-15% of maxillofacial injuries; 66% of patients with frontal sinus injuries have associated maxillofacial fractures [1]. The exact incidence of penetrating and perforating injuries to the head in the general population is unknown, but current estimations indicate that fire arms injury account for 4.6% from the population, puncture wound, stab wound, etc., caused 0.4% of this kind of brain injuries [2]. When a patient presents with varying degrees and forms of injury, the physician and healthcare facility provide needed medical attention. Injuries caused by direct physical trauma are evaluated clinically in the outpatient or emergency department of a hospital [3]. Wounds can

be divided into three types: stab wounds, cuts, and laceration wounds. Wounds caused by sharp objects are usually easy to distinguish from wounds caused by blunt objects [4]. This type of trauma caused by several objects such as knives, sword, machetes, or other objects that have slicing properties that cause loss of tissue continuity [5]. In trauma forensics, a key determination would be whether an incised injury is accidental or non-accidental. The pattern of distribution of the injuries on the body and their severity may offer a useful clue [6]. Injury can lead to an act of persecution which can endanger the safety of the lives of the public, so this action is subject to a criminal act based on the Criminal Code in Indonesia Article 351 [7]. Persecution is punishable by a maximum imprisonment of two years and eight months or a maximum fine of four thousand five hundred rupiahs; If the act results in serious injury, the guilty person is threatened

**Received date:** 15 October 2023; **Accepted date:** 24 October 2023; **Published date:** 31 October 2023

**Citation:** Syahputra N, Petrus A (2023). A Rare Case of Unintentional Victim of Brawl with Frontal Bone Injury Cause of Stray Arrow. SunText Rev Cardiovasc Sci 3(1): 115.

**DOI:** <https://doi.org/10.51737/cardiovascular.2023.015>

**Copyright:** © 2023 Syahputra N, et al. This is an open-access article distributed under the terms of the Creative Commons Attribution License, which permits unrestricted use, distribution, and reproduction in any medium, provided the original author and source are credited.

with a maximum imprisonment of five years; If it results in death, it is punishable by a maximum imprisonment of seven years; Persecution is equated with deliberately damaging health; Attempting to commit this crime is a criminal offense. In upholding justice for victims of persecution, Visum Repertum based on expert's observation and findings must be made as evidence to be brought to court. This case report will present a rare case of an unintentional victim of brawl with frontal bone injury cause of stray arrow.

### Case Illustration

A 19 years old male with an arrow in his forehead was taken to emergency room at Haji Adam Malik Hospital Medan on 26 December 2022. The victim was on his way home from work to home. At that time there was a brawl between residents at the crossroad of Jalan Pasar Lama, Medan Belawan District. The victim forced himself to continue through the road and finally was hit by an arrow in the forehead.

### External examination

**Vital Sign:** Patient was found with full consciousness (Glasgow Coma Scale = 15 (E: 5, V: 4, M: 6)), stable emotional state, and cooperative. Blood pressure was 120/70 mmHg, heart rate 88 beats/minute, respiratory rate was 18 times/minute, and temperature was 36°C.

### Localized examination

There was a wound caused by a sharp object (arrow) which was still stuck in the middle of the forehead about the midline of the body. After the arrow removed, was found the wound edges was flat, no tissue bridges were found. The size of the wound was 2 cm in length, 1 cm in width, with depth 2.8 cm. Bruises on the edge of the wound were not found.

There were no sign of violence in other body parts Patient referred to Neurosurgery Department of Adam Malik Hospital Medan for further treatment.

### Additional examination

Patient came to emergency room of Haji Adam Malik Hospital Medan and got head x-ray examination to determined vital organs involvement. From the head x-ray, epidural hemorrhage was not found. The victim referred to Neurosurgery Department of Haji Adam Malik Hospital Medan and did additional examination before further treatment, which were: Multislice CT Scan Head/Brain with conclusion: opaque corpus alineum with metal artefact surrounded penetrate os frontal until intracranial. There was no intracerebral hemorrhage seen. 3D Contrast Examination (Shoulder-Face-Pelvic-Lumbal) with conclusion: foreign object

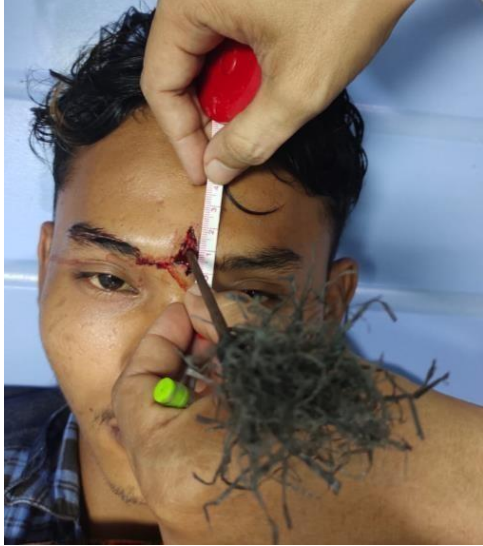with arrow shape caused metal artefact surrounded with os frontal penetration.

Based on the additional examination, an illustration of the foreign object found in victim has been made.

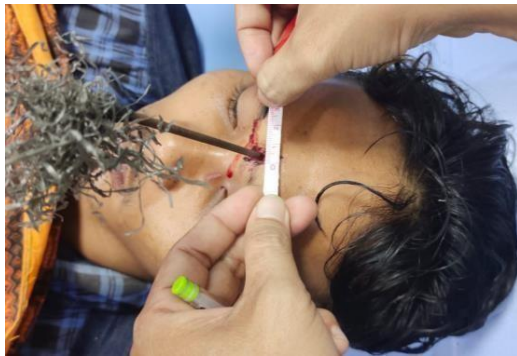### Discussion

In this case a 19 years old male has been examined at the Emergency Room of Haji Adam Malik Hospital Medan. From the results of external examination was found a stab wound due to sharp object in the middle of the forehead about the body's midline. This patient experienced sharp trauma which was marked by an object whose surface was capable to slice and cause a discontinuity of the tissue. The edge of wound was sharp, when the edge linked it will become tight and could form straight line with slight curves. No tissue bridges were found, and the area around the wound wasn't bruised and can be seen in (Figures 1 and 2). Based on the wound description in this case, it can be concluded that the victim got a stab wound. A wound with depth exceeds the length of the wound as a result of a tool with sharp tip and sharp edges as in this case, known as stab wound. In this case the object was an arrow. The depth of the wound could not be measured because the arrow still stuck in the victim's forehead. From the measurement result the arrow's length were 15.2 cm (6 inches) as shown in (Figure 3). On Figure 4 included an illustration of weapon (arrow) on victim, with an estimation of arrow's depth to the victim's forehead. Based on the illustration, it was estimated the rest of the arrow which penetrate the victim's forehead around 2.8 cm (1.10 inch). So the estimation of total weapon's (arrow) length was 18 cm (7.08 inch). This estimation was made because triage doctor has limited examination for the victim since the victim directly referred to Neurosurgery Department of Haji Adam Malik Hospital Medan. Based on the wound qualification the injury sustained as moderate degree injury. A moderate degree of injury defined as the wound that causes disease which prevent the victim to carrying out a job, position or temporary livelihood. This based on Indonesia's Criminal Code article 351. This case became interesting because the victim came to emergency room with full consciousness. Facial injuries are rarely life-threatening; yet there should be high suspicion based on the mechanism and energy impact of the injury. Since there are multitude of organs and structure that may be involved, interdisciplinary care has become the standard [8]. Intracranial involvement should be suspected when posterior wall is fractured. Those cases have more complications and poor clinical outcome than fractures involving only the anterior wall. Penetrating head trauma caused by non-missile, low-velocity objects represents a rare pathology among civilians, with better outcome because of more localized primary injury, and is usually caused by violence, accidents, or even suicide attempts [9]. Most of the patients with stab wound to the head are in a good general

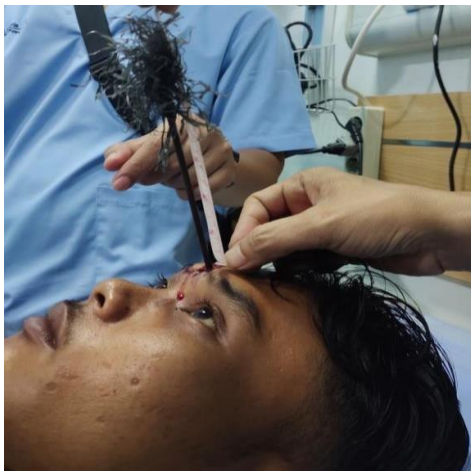condition. They are awake, responsive, and hemodynamically stable, except for the possible neurological deficits. The risk of local wound infections, meningitis, ventriculitis, or cerebral abscess is particularly high among penetrating head trauma patients because of the presence of contaminated foreign objects like skin, hair and bone fragments.




**Figure 1:** The measurement of wound length on victim.



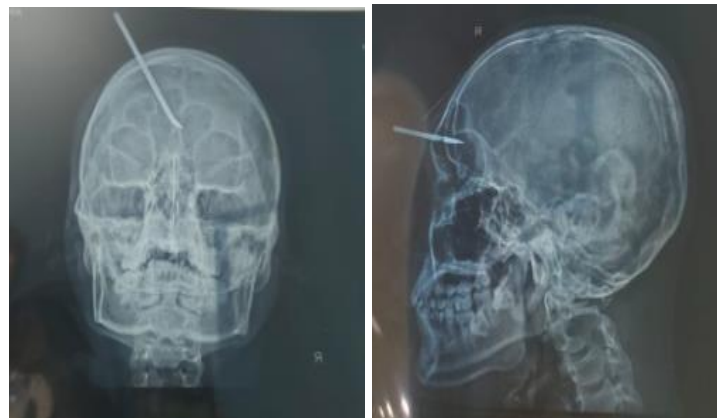**Figure 2:** The measurement of wound width on victim.



**Figure 3:** The measurement of sharp object (arrow) length.



**Figure 4:** Weapon's Illustration on Victim.



**Figure 5:** Head X-Ray.

In head injury patient management, physician needs to prevent or reduce conditions that can worsen outcomes of the patient. Initial examination should include a proper history of the injury (date, time, duration of loss of consciousness if present, seizure, any comorbid if exist, and also the usage of anticoagulants and antiplatelet agents). A complete physical examination should be performed including neurological examination [10]. In the pre-hospital setting, or in non-trauma facilities, stabilize, but, do not remove penetrating objects such as knives. Patients should be transported quickly to a location capable of providing definitive care. Early recognition of high-risk mechanisms, early imaging, and early evaluation at trauma center may improve outcomes [11,12]. A Computed Tomography (CT) scan of the head obtained if the patient is hemodynamically stable (Figures 4 and 5). A CT scan can adequately identify the extent of the intracranial injury and can also determine the relationship between the penetrating object and the intracranial structures. In the result section, we include an illustration of weapon's (arrow) length and the impact for the victim's; the measurement based on research of average adult male frontal sinuses measurement with



CT scan. On adult male the average of frontal sinus length is  $19.8 \pm 8.7$  mm; the width is  $32.8 \pm 8.7$  mm; and the height is  $29.7 \pm 8.8$  mm. But this data will differ based on sex, age, race, ethnic, and an individual nationality [13]. In this case further treatment and examination decision came from neurosurgery department. Forensic Medicine plays a role in determining the casual relationship between an action and the consequences that will result from the action, whether it causes injury to the body, or causes health problems, or causes the death of a person, where these consequences should be presumed to have occurred a crime occurred. The forensic role can provide assistance in relation to the judicial process in matters of which include identifying whether there is persecution or not, just like this case [14]. But, there was no further judicial process in this case due to patient consent.

## Conclusion

A 19 years old male with an arrow in his forehead was taken to emergency room at Haji Adam Malik Hospital Medan. This case was rare since the arrow was unintentionally hit the victim and patient came to hospital with full consciousness. Patient referred to neurosurgery department and there was no judicial process in this case due to patient consent.

## Recommendation

Based on the medicolegal aspect of Forensic Medicine, it is necessary for victims take a legal action for the loss they suffer from an accident or crime settings. In this case the victim had moderate degree injury which defined as the wound that causes disease which prevent the victim to carrying out a job, position or temporary livelihood based on Indonesia's Criminal Code article 351. In upholding justice for victims of persecution, Visum et Repertum based on expert's observation and findings must be made as evidence to be brought to court. But, since the victim refused to take a legal action there was no one took the responsibility of the accident. At the end, a doctor should not provoke a patient with their decision, but a doctor has a responsibility to educate patients before they make a fair decision for their life.

## References

1. Sathyanarayanan R, Raghu K, Deepika S, Sarath K. Management of frontal sinus injuries. *Annals of Maxillofacial Surgery*. 2018; 8: 276-280.
2. Yarandi K, Jelodar S, Khalatbari M, Rasras S, Ilkhchi R, Amirjamshidi A. Stab wounds to the head; Case series, review of literature, and proposed management algorithm. *Asian J Neurosurg*. 2018; 13: 754-759.
3. Eze UO, Abraham K. Trauma Forensics in Blunt and Sharp Force Injuries. 2022.
4. Zansen J. Examination of victims of sharp trauma. *Indones J Multidiscip Sci*. 2022; 1: 1676-1687.
5. Payne-James JJ, Stark MM. Clinical Forensic Medicine: History and Development. *Clinical Forensic Medicine: A Physician's Guide*. 2020; 1-21.
6. Putri JH, Hamdy IH, Haris IA, Nahdah J, Putri JC. Clinical Forensic Assessment of Victim with Sharp Force Injury (A Case Report). *International Islamic Medical J*. 2022; 3: 132-138.
7. Kementerian Hukum dan HAM. Kitab Undang-Undang Hukum Pidana (Kuhp). *Kitab Undang Huk Pidana*. 2018; 5: 1689-1699.
8. Truong TA. Initial Assessment and Evaluation of Traumatic Facial Injuries. *Semin Plast Surg*. 2017; 31: 69-72.
9. Fahde Y, Laghmari M, Skoumi M. Penetrating head trauma: 03 rare cases and literature review. *Pan Afr Med J*. 2017; 28.
10. Alao T, Waseem M. Penetrating Head Trauma. *StatPearls*. 2016; 42-48.
11. Puffenbarger MS, Ahmad FA, Argent M, Gu H, Samson C, Quayle KS, et al. Reduction of Computed Tomography Use for Pediatric Closed Head Injury Evaluation at a Nonpediatric Community Emergency Department. *Acad Emerg Med*. 2019; 26: 784-795.
12. Voss J, Thieme N, Doll C, Hartwig S, Adolphs N, Heiland M, et al. Penetrating Foreign Bodies in Head and Neck Trauma: A Surgical Challenge. *Craniofacial Trauma Reconstr*. 2018; 11: 172-182.
13. Abdalla MA. Age differences of human frontal sinus measurements using CT scan. *J Adv Med Biomed Res*. 2021; 29: 293-301.
14. Trisnadi S. *JPH: Jurnal Pembaharuan Hukum*. 2021; 8: 157-171.