



# Treatment Case of Fitz Hugh Curtis Syndrome Presenting as Cornual Ectopic

Gomathi P\*

Specialist Gynaecologist DGO, DNB OG, MRCOG, Bachelor in Gynecological Endoscopy, UK

\*Corresponding author: Gomathi P, Specialist Gynaecologist DGO, DNB OG, MRCOG, Bachelor in Gynecological Endoscopy, UK; E-mail: [asgomathi@gmail.com](mailto:asgomathi@gmail.com)

Received date: 20 July 2022; Accepted date: 16 September 2022; Published date: 25 September 2022

Citation: Gomathi P (2022). Treatment Case of Fitz Hugh Curtis Syndrome Presenting as Cornual Ectopic. SunText Rev Case Rep Image 3(3): 152.

DOI: <https://doi.org/10.51737/2766-4589.2022.052>

Copyright: © 2022 Gomathi P. This is an open-access article distributed under the terms of the Creative Commons Attribution License, which permits unrestricted use, distribution, and reproduction in any medium, provided the original author and source are credited.

## Abstract

Fitz-Hugh–Curtis syndrome (FHCS) is defined as peri-hepatic inflammation due to disseminated PID; with Chlamydia trachomatis and Neisseria gonorrhoea being the main aetiological agents. The main mechanism of this pathology is attributed to hemato-lymphatic and peritoneal spread of pelvic infections to the liver and hyper-immune response to Chlamydia trachomatis infection with both processes leading to peri-hepatic and liver capsular inflammation. Typically, patients with FHCS are women of childbearing age who visit a hospital with complaints of acute pain or chronic tenderness in the right upper abdomen. A thorough history and a high index of suspicion are necessary to reach an appropriate diagnosis. Right upper quadrant abdominal pain is a symptom of myriad pathologies including, but not exclusive to, cholecystitis, pleurisy, right pyelonephritis, subphrenic abscess, or herpes zoster infection, making an assessment for FHCS particularly difficult.

**Keywords:** Fitz-Hugh–Curtis syndrome; Pelvic infections; Liver capsular

## Objective

The incidence of ectopic presenting with Fitz-hugh-curtis syndrome is 14-34%. The case presented here is to reiterate the need for early diagnosis and treatment of PID to prevent major complications like ectopic gestation.

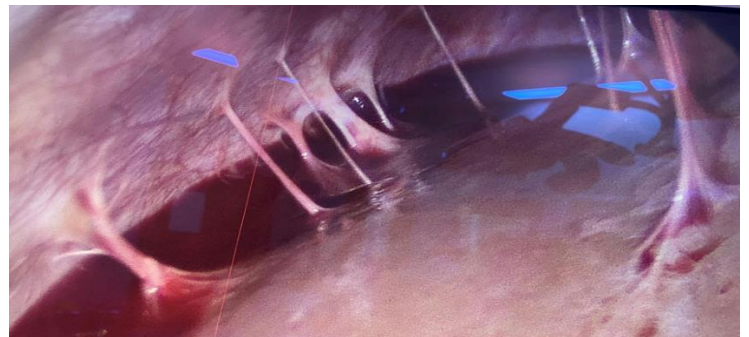
## Case Report

A 21 Year old Primi, married 1yr, diagnosed to have right ectopic gestation medical management done with injection methotrexate as per protocol, on serial follow up beta hcg was reducing, after 3 weeks patient came with history of acute pain abdomen, ultrasound revealed ruptured ectopic, beta hcg was 1411, proceeded with laparoscopy which revealed right cornual ectopic around 2cms with omental adhesions over it and proceeded with total salpingectomy with cornual resection after taking encircling sutures at cornual end. Left tube was found adherent to left round ligament and omentum, the same released and anatomy restored. Further evaluation revealed strings of adhesions seen between anterior surface of liver and anterior abdominal wall very typical

of Fitz -hugh -curtis syndrome as a consequence of chronic Pelvic inflammatory disease (PID) seen in this patient. Post-operative period was uneventful. Patient and her partner was treated for chronic PID as per CDC guidelines.

## Discussion

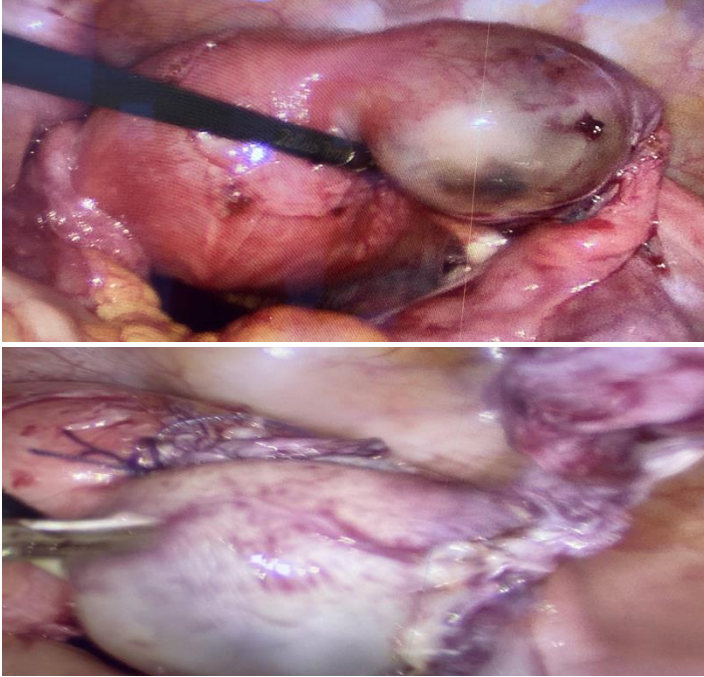
Fitz-Hugh-Curtis syndrome is a condition in which, as a result of pelvic inflammatory disease, the liver capsule becomes involved with inflammatory exudate that later leaves violin string adhesions.



Citation: Gomathi P (2022). Treatment Case of Fitz Hugh Curtis Syndrome Presenting as Cornual Ectopic. SunText Rev Case Rep Image 3(3): 152.

**SUNTEXT REVIEWS**

Although in the past *Neisseria gonorrhoea* was thought to be the only etiological agent, recent data indicate that *Chlamydia trachomatis* may play an important role in perihepatitis. Perihepatic adhesions may be an after effect of the acute hepatic episode, and because the cause of ectopic pregnancy is thought to be salpingitis, women with an ectopic pregnancy may have a higher prevalence of coexisting perihepatic adhesion [1].



Direct observation of the liver and pelvis through laparoscope is the most definitive method of diagnosing salpingitis and perihepatitis. Standard treatment regimens recommended for salpingitis are adequate also for treatment of perihepatitis.

### Conclusion

Pelvic inflammatory disease can lead to potentially serious complications like ectopic pregnancy, subfertility, chronic pelvic pain and psychological morbidity. A thorough history and a high index of suspicion are necessary to reach an appropriate diagnosis. It should be treated proactively including partner tracing to avoid such dreadful complications.

### References

1. NORD-National rare disease database for Fitz-hugh-curtis syndrome.
2. STI Treatment Guidelines – Pelvic Inflammatory Disease (PID). 2021.
3. Elson CJ, Salim R, Potdar N, Chetty M, Ross JA, Kirk EJ. Diagnosis and management of ectopic pregnancy. *BJOG: An Int J Obstetrics Gynaecol.* 2016; 123: e15-e55.