



# Hypofractionated Radiosurgery Re-Irradiation in Large Solitary Brain Metastasis from HER2 Positive Breast Carcinoma

Marinova L\*, Vassileva V, Petrov V and Gabrovski I

Medical Oncology Clinic, Department of Radiation and Metabolic Brachytherapy, UMHAT Queen Joanna Sofia, Bulgaria

\*Corresponding author: Marinova L, Medical Oncology Clinic, Department of Radiation and Metabolic Brachytherapy, UMHAT Queen Joanna Sofia, Bulgaria; E-mail: [rad\\_marinova@abv.bg](mailto:rad_marinova@abv.bg)

## Abstract

In improved therapeutic capabilities, late progression of locally advanced HER2 positive breast cancer (BC) is increasingly diagnosed after complex treatment by expression of late solitary brain metastasis (BM). We present a 35-year-old woman with left invasive ductal BC /pT2N1M0, grade G3 with positive estrogen, progesterone and HER2 receptors expression. Complex treatment was carried out, including radical mastectomy with axillary dissection followed by adjuvant treatment- chemotherapy (Ch), radiotherapy (RT), targeted therapy (TT) with trastuzumab and endocrine therapy with LHRH agonist plus tamoxifen. After 8 years a single brain metastasis has been found, extirpated and histologically verified. Postoperative whole-brain radiotherapy (WBRT) up to total dose (TD) 25 Gy with daily dose (DD) 2,5 Gy and boost in brain metastasis up to biologically effective dose/BED 49,5Gy was conducted. August-October 2020 after 1 year of WBRT, against the background of complex treatment with 2 targeted agents/ trastuzumab/pertuzumab and endocrine therapy, CT visualized elevated vasogenic peritumor edema with the progress of the mass effect. The only therapeutic alternative was re-irradiation of brain metastasis by hypofractionated radiosurgery (HFRS). The purpose of this article is to present the efficient healing combination of targeted therapy and HFRS re-irradiation in late solitary BM from HER2 positive BC, not only in terms of local control but also on prolonged survival.

**Keywords:** Hypofractionated radiosurgery; Large solitary brain metastasis; Re-irradiation; HER2 positive breast carcinoma; Targeted therapy

## Introduction

Improved overall survival rates among patients with brain metastases (BM) have led to higher rates of salvage re-irradiation in patients with local failure [1]. Large BM can be defined according to their diameter or volume, with lesions measuring either  $\geq 2$  or  $\geq 3$  cm in diameter or  $\geq 4$  cm<sup>3</sup> [2-5]. Postoperative whole brain radiation therapy (WBRT) should be considered to reduce the risk of tumour recurrence for patients who have undergone resection of a single brain metastasis [6]. Radiosurgery (RS) is increasingly becoming the preferred treatment for BM, not only for its efficacy in providing good local control (LC), but also for its limited long term toxicity profile, especially regarding neurocognitive function when compared to WBRT [7-9]. Post

operatively, cavities can easily have a diameter  $>3-4$  cm, rendering a RS treatment difficult. Larger cavities are thus usually treated with a hypo fractionated treatment with doses ranging from 24 Gy in 3 fractions to 36 Gy in 6 fractions [10-12]. The purpose of this article is to present the efficient healing combination of targeted therapy and hypo fractionated radiosurgery (HFRS) re-irradiation in late solitary BM from HER2 positive breast carcinoma (BC), not only in terms of LC, but also on prolonged survival.

## Clinical Case

We present a 35-year-old woman diagnosed in 2011 with invasive ductal left BC/pT2N1M0, grade G3 with positive estrogen, progesterone and HER2 receptors expression. Complex treatment

Received date: 16 March 2022; Accepted date: 21 March 2022; Published date: 27 March 2022

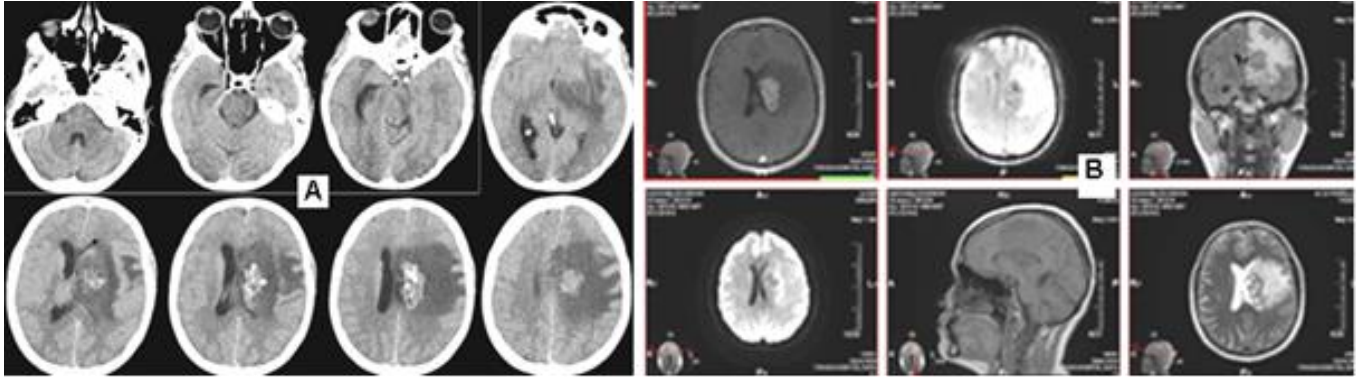
**Citation:** Marinova L, Vassileva V, Petrov V, Gabrovski I. (2022) Hypofractionated Radiosurgery Re-Irradiation in Large Solitary Brain Metastasis from HER2 Positive Breast Carcinoma. SunText Rev Med Clin Res 3(1): 149.

**DOI:** <https://doi.org/10.51737/2766-4813.2022.049>

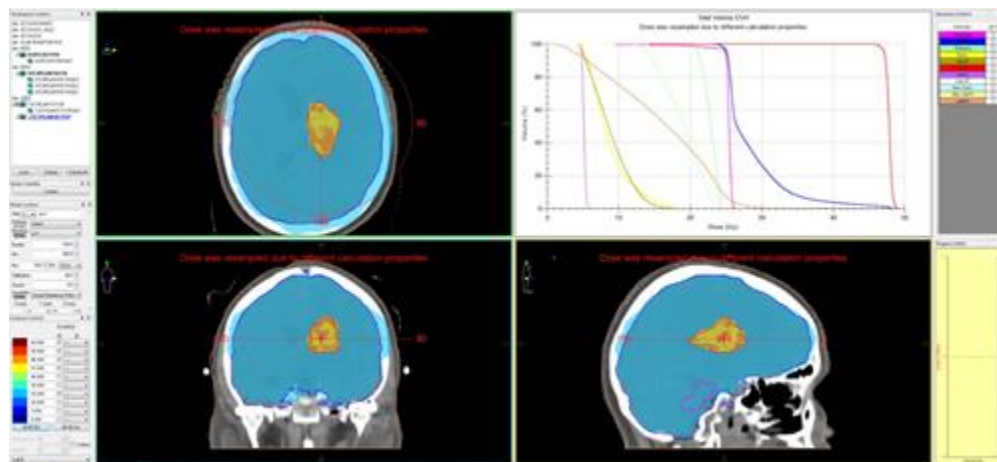
**Copyright:** © 2022 Marinova L, et al. This is an open-access article distributed under the terms of the Creative Commons Attribution License, which permits unrestricted use, distribution, and reproduction in any medium, provided the original author and source are credited.

was carried out, including radical mastectomy with axillary dissection, followed by adjuvant treatment /chemotherapy (Ch), radiotherapy (RT), targeted therapy (TT) with trastuzumab and endocrine therapy with LHRH agonist plus tamoxifen. In 2015 the patient has carried out surgical excision of a package increased left supraclavicular lymph nodes with histopathological

result lymphatic metastases from invasive ductal carcinoma. Complex treatment is continued with Ch, bilateral adnexectomy, TT with herceptin and perjeta and endocrine arimidex therapy. In 2017 clinical remission has been achieved. In February 2019, a headache appeared, and CT and MRT visualized data for a solitary brain metastasis (Figure 1).



**Figure 1:** A / CT of the brain; B / MRI of the brain / February 2019 - Heterogeneous contrast-cumulative periventricular lesion, measuring 5cm / 3 cm with calcificates, surrounded by vasogenic edema and mass-effect.



**Figure 2:** Intensity modulated whole-brain radiotherapy (WBRT) by the VMAT method up to TD 25 Gy with daily dose (DD) 2.5 Gy and boost in brain metastasis and lateral brain ventricles with DD 2 Gy up to biologically effective dose/BED 49,5Gy.

In April 2019, partial tumor resection was performed. Intraoperative: Line skin incision parasagittal on the right, 5 cm. front and 4 cm. behind the skull coronal seam. Sinus sagittalis superior (SSS) is visualized. Dura mater opened arched with a base to the middle line. Multiple bridge veins draining to the SSS were found, hampering interhemispheric access. The right frontal lobe is separated and in depth the two arteries cerebri anterior are dissected along the corpus callosum. A callosotomy was performed. It reached the left lateral ventriculus and located foramen Monroe. It came across an intraaxial tumor formation touching the lateral wall of the left lateral ventricle. During the months May-June 2019, whole-brain radiotherapy (WBRT) was conducted up to total dose (TD) 25 Gy with daily dose (DD) 2.5 Gy and boost in brain metastasis (BM) and lateral brain ventricles

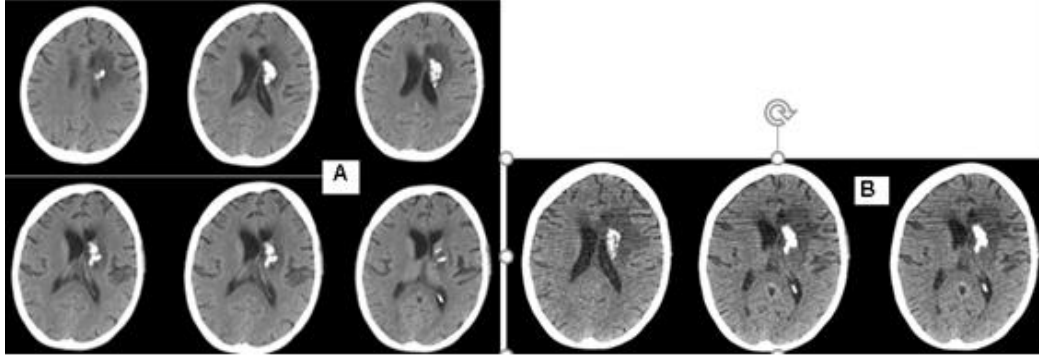
with DD 2 Gy up to biologically effective dose/BED 49,5Gy (Figure 2).

RT is combined with TT /herceptin 600mg. and perjeta 840 mg. 4 months after the WBRT with boost of brain metastasis, the brain CT establishes a reduction in its size, visibly reduced mass effect and reduced perifocal edema on the left (Figure 3).

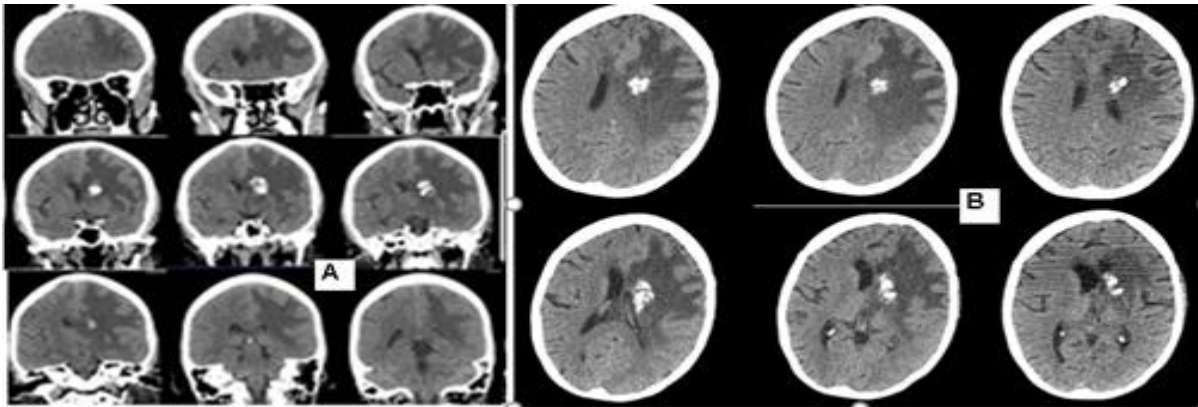
After 3 months, the brain CT from February 2020 reported an increase left perifocal vasogenic edema. In August 2020 the patient had a headache and the CT visualized progression of vasogenic edema and frontoparietal mass-effect, causing compression and dislocation on the middle line to the right. In October 2020 there was a progression of vasogenic edema and parietal growth of the mass- effect (Figure 4).

From 2019 until October 2020 the patient was treated with TT with herceptin and pertuzumab and a daily dose of 4 mg. Dexamethasone. After consulting with neurosurgeons, the solitary brain metastasis was assessed as an inoperable, and we decided that the only alternative treatment approach was HFRT despite the previous WBRT with boost in BM. In January 2021 we

conducted a HFRT with 3 dose fractions of 6 Gy for three consecutive days. For planning target volume (PTV) definition, a margin of 1 mm around the contrast-enhancing MRI metastasis volume (GTV) was used. In  $\alpha / \beta$  10 for metastasis, the biologically effective dose BED was 28, 8 Gy and the equivalent dose (EQD2) was 24 Gy (Figure 5).



**Figure 3:** CT of the brain A/ 4 months after the WBRT with boost/ October 2019 -A reduction in metastasis size, visibly reduced mass-effect and reduced perifocal edema on the left; B/ 7 months after the WBRT with boost / February 2020- An increase left perifocal vasogenic edema.



**Figure 4:** CT of the brain A / August 2020- Progression of vasogenic edema and frontoparietal mass-effect causing compression and dislocation on the middle line to the right; B / October 2020 with progression of vasogenic edema and parietal growth of the mass-effect.

The total equivalent dose EQD2 for BM from the two RT stages: WBRT with boost in BM 49.5 Gy + 24 Gy from HFRT = 73, 5 Gy. The patient continued her treatment with TT/ herceptin and pertuzumab. Three months after radiosurgery, the brain MRI of April 2021 reported brain lesion to left to falx cerebri with central necrosis, annularly contrasted with vasogenic edema in left hemisphere and mass -effect on left lateral brain ventricle (Figure 6).

MRI from August 2021 was without dynamics (Figure 7).

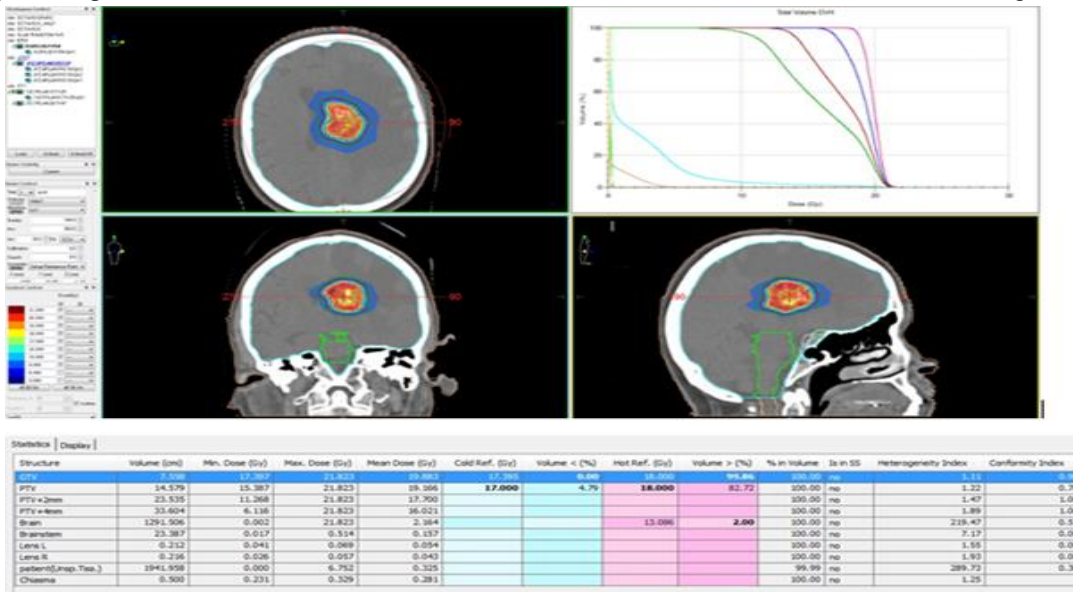
From August 2021 to February 2022, TT continues with herceptin and lapatinib. Currently, the patient is in a good overall condition, without headaches, with daily maintenance dose 4 mg dexamethasone, with difficulty in speaking, without deviations in neurological status.

## Discussion

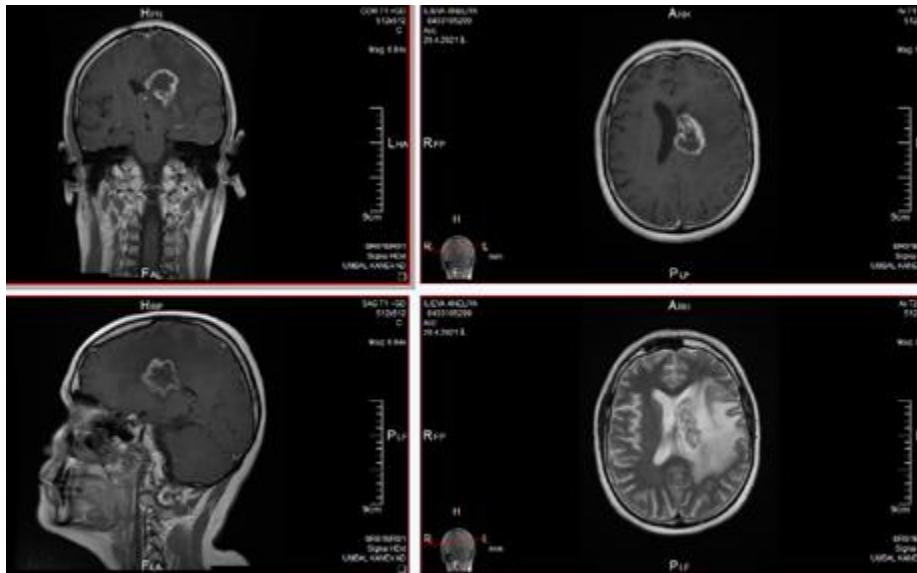
Brain metastases (BMs) are the most frequent brain tumors, and, throughout disease course, 20–40% of cancer patients will develop a BM [13]. Surgical excision should be considered for patients with good performance status, minimal or no evidence of extracranial disease, and a surgically accessible single brain metastasis amenable to complete excision [6]. After surgery, adjuvant whole-brain radiotherapy (WBRT) allows to significantly reduce local and brain recurrence rates, as well as the risk of death from neurological cause [6,14,15]. Although different fractionation schedules of WBRT do not influence survival, it appears that escalating the dose to the metastatic lesions increases intracerebral control as well as OS, compared to WBRT alone [17,18]. WBRT with 3D conformal boost is a feasible technique which improves the quality of life (QOL) of patients with a reduced number of brain metastases, regardless of the fractionation regime or the total dose administered to the

metastatic lesions [19]. HFRS is an efficient treatment option for patients with operated BM [20]. Brain metastases larger than 3 cm in diameter or producing more than 1 cm of midline shift are

typically not considered acceptable candidates for single fraction radiosurgery (RS) due to an insufficient volume response and an increased risk for cerebral edema following RS [21-23].



**Figure 5:** Hypofractionated radiosurgery (HFRS) with 3 dose fractions of 6 Gy for three consecutive days. For planning target volume (PTV) definition, a margin of 1 mm around the contrast-enhancing MRT metastasis volume (GTV) was used. In  $\alpha / \beta 10$  for brain metastasis, the biologically effective dose BED is 28,8Gy and the equivalent dose (EQD2) is 24 Gy.



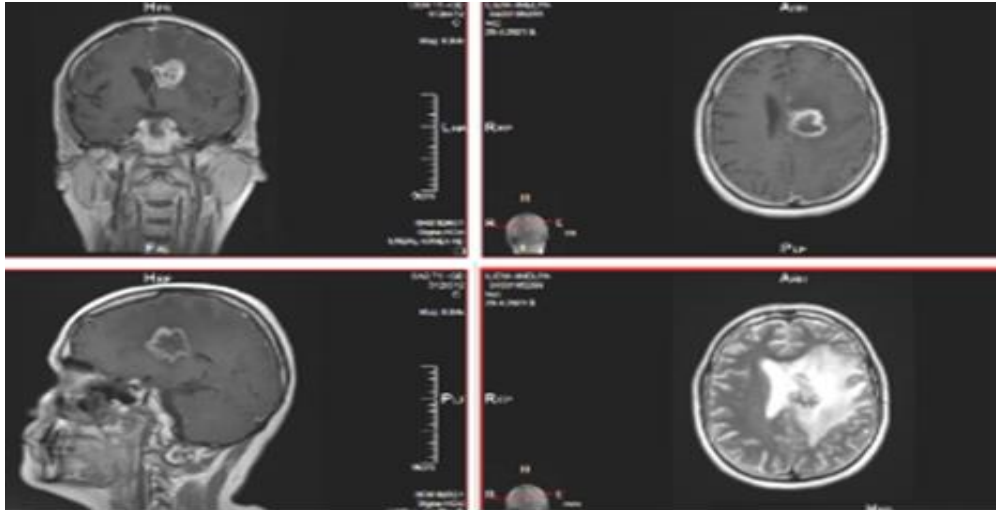
**Figure 6:** The brain MRI / April 2021 - The brain lesion to left to falx cerebri with central necrosis, annularly contrasted with vasogenic edema in left hemisphere and mass -effect on left lateral brain ventricle.

A possible advantage of WBRT over HFRS in the post-operative setting is the risk of leptomeningeal disease. The rate of leptomeningeal spread to meninges and cerebrospinal fluid in patients treated with WBRT is 5–12% vs. 14–28% [24-26]. In the presented clinical case, postoperative WBRT was required, due to the fact that partially operated brain metastasis was localized immediately adjacent to the wall of the lateral ventricle, which

increased the risk of liquid and leptomeningeal metastases. For the same reason, we also conducted the boost in metastasis and left lateral ventricle to biologically effective dose BED 49,5 Gy. After 7 months from the completion of the WBRT with boost in BM, a brain CT found a reduction in BM, as well as the mass-effect, but increased peritumoral vasogenic edema. In August 2020, the patient has a headache. CT reported progression of vasogenic

edema and a front-parietal mass-effect, causing compression and dislocation of the brain middle line. In October 2020 a progression of vasogenic edema with parietal growth of the mass-effect was clearly diagnosed. The patient has a strong headache, despite the intake of dexamethasone / 3 x 4 mg. and anti-edema therapy with mannitol. Due to the axial tumor localization with high surgery risk, the only therapeutic alternative was to realize HFRS with three 6 Gy fractions for three consecutive days. In  $\alpha / \beta$  10 for metastasase, the biologically effective dose BED is

28,8Gy and the equivalent dose (EQD2) is 24 Gy. The total equivalent dose EQD2 for metastasis from the two RT stages: WBRT with boost in brain metastasis 49.5 Gy + 24 Gy of HFRT = 73,5 Gy. Data exist concerning the re-irradiation of brain tumors to a median cumulative BED (biological equivalent dose in 2Gy fractions) of 200Gy, with at least one year between the two treatments. Longterm complications related to the retreatment were seen in patients with a BED<sub>2</sub>>204Gy ( $\alpha$ : $\beta$ =2 Gy) [27].



**Figure 7:** The brain MRI / August 2021 - 8 months after HFRS- the MR image without substantial dynamics with slightly increased vasogenic edema.

Re-irradiation is frequently undertaken for isolated brain relapses. A meta-analysis of brain re-irradiation found no cases of necrosis if the total dose (TD) lower than 100Gy (2 Gy daily fraction dose;  $\alpha$ : $\beta$  = 2 Gy) was [28]. In humans, there is evidence that the risk of myelopathy is low at radiation doses up to a median cumulative BED 135Gy, when the time interval between reirradiation is not shorter than six months and the dose for each course is <98 Gy BED<sub>2</sub> [29]. The stereotactic re-irradiation or WBRT was the only factor associated with an increased risk of developing a radiation necrosis ( $p < 0.001$ , Fisher exact test). Among patients that received HFRS exclusively, the rate of radiation necrosis at the end of follow-up was 6.9% and among the 7 patients treated with stereotactic re-irradiation in the surgical cavity, 4 (57%) presented with a radiation necrosis [20]. In the presented clinical case after 8 months of the cerebral metastasis re-irradiation with a HFRT up to total equivalent dose EQD2 73.5 Gy, MRI reported annular contrasted brain lesion to the left falx cerebri with central necrosis, vasogenic edema in left hemisphere and mass -effect on the left lateral ventricle. At present, the patient is in a good overall condition and quality of life, no headache, a daily maintenance dose of 4 mg of dexamethasone, with difficult speeches, and no deviations in neurological status. We believe that the difficulty in speaking is due to violations of the corpus calosum during the partial surgery as well as the subsequent necrosis in metastasis

due to HFRS. It is known that the two hemispheres in the human brain are connected by a thick bundle of nerve fibres called the corpus calosum that ensures both sides of the brain can communicate and send signals to each other. We observe the so-called disconnection syndrome that occurs, when the connection between the two hemispheres is disrupted, either as a result of brain surgery, stroke or trauma.

## Conclusion

Later-performing solitary brain metastases in locally advanced HER2 positive breast cancer are diagnosed as a disease progression, despite prolonged complex treatment, including surgery, chemotherapy, radiotherapy, hormone therapy and targeted therapy. In the case of inoperable brain metastasis, locally applied to the brain ventricles, it is necessary to allocate WBRT with a boost in metastasis in order to prevent liquid and leptomenigeal metastases. Radiotherapy should be combined with targeted therapy, which needs to continue during the period after its completion. In a new progression of brain metastasis, after 6 months of previous radiotherapy, it is possible to conduct HFRS re-irradiation up to a median cumulative BED 135 Gy. The remarkable in this clinical case is that as a result of complex treatment, including radiotherapy and targeted therapy, we have

achieved a 3-year survival after diagnosis of solitary radical nonperable brain metastasis.

## References

1. Tseng, J. Detsky. Rates of Radionecrosis in re-irradiation of brain metastases using hypofractionated stereotactic radiotherapy. *Int J Rad Oncol Biol Phys.* 2020; 108: 720.
2. Choi CY, Chang SD, Gibbs IC, Adler JR, Harsh GR, IV, Atalar B, et al. What is the optimal treatment of large brain metastases. An argument for a multidisciplinary approach. *Int J Radiat Oncol Biol Phys.* 2012; 84: 688-693.
3. Han JH, Kim DG, Chung HT, Paek SH, Park CK, Jung HW, et al. Radiosurgery for large brain metastases. *Int J Radiat Oncol Biol Phys.* 2012; 83: 113-120.
4. Lee CC, Yen CP, Xu Z, Schlesinger D, Sheehan J. Large intracranial metastatic tumors treated by Gamma Knife surgery: outcomes and prognostic factors. *J Neurosurg.* 2014; 120: 52-59.
5. Navarria P, Pessina F, Cozzi L, Ascolese AM, De Rose F, Fogliata A, et al. Hypo-fractionated stereotactic radiotherapy alone using volumetric modulated arc therapy for patients with single, large brain metastases unsuitable for surgical resection. *Radiat Oncol.* 2016; 11: 76.
6. Mintz A, Perry J, Spithoff K. Management of single brain metastasis: a practice guideline. *Curr Oncol.* 2007; 14: 131-143.
7. Brown PD, Jaeckle K, Ballman KV, Farace E, Cerhan JH, Anderson SK, et al. Effect of radiosurgery alone vs radiosurgery with whole brain radiation therapy on cognitive function in patients with 1 to 3 brain metastases: a randomized clinical trial. *JAMA.* 2016; 316: 401-409.
8. Chang EL, Wefel JS, Hess KR, Allen PK, Lang FF, Kornguth DG, et al. Neurocognition in patients with brain metastases treated with radiosurgery or radiosurgery plus whole-brain irradiation: a randomised controlled trial. *Lancet Oncol.* 2009; 10: 1037-1044.
9. Aoyama H, Tago M, Kato N, Toyoda T, Kenjyo M, Hirota S, et al. Neurocognitive function of patients with brain metastasis who received either whole brain radiotherapy plus stereotactic radiosurgery or radiosurgery alone. *Int J Radiat Oncol Biol Phys.* 2007; 68: 1388-1395.
10. Sloan JS, Sloan AE, Davis FG, Vignneau FD, Lai P, Sawaya RE, et al. Incidence proportions of brain metastases in patients diagnosed (1973 to 2001) in the Metropolitan Detroit Cancer Surveillance System. *J Clin Oncol.* 2004; 22: 2865-2872.
11. Connolly EP, Mathew M, Tam M, King JV, Kunnakkat SD, Parker EC, et al. Involved field radiation therapy after surgical resection of solitary brain metastases—mature results. *Neuro Oncol.* 2013; 15: 589-594.
12. Hartford AC, Paravati AJ, Spire WJ, Li Z, Jarvis LA, Fadul CE, et al. Postoperative stereotactic radiosurgery without whole-brain radiation therapy for brain metastases: potential role of preoperative tumor size. *Int J Radiat Oncol Biol Phys.* 2013; 85: 650-655.
13. Patchell RA. The management of brain metastases. *Cancer Treat Rev.* 2003; 29: 533-540.
14. Kocher M, Soffiatti R, Abacioglu U, Villa S, Fauchon F, Baumert BG, et al. Adjuvant whole-brain radiotherapy versus observation after radiosurgery or surgical resection of one to three cerebral metastases: results of the EORTC 22952-26001 study. *J Clin Oncol.* 2011; 29: 134-141.
15. Patchell RA, Tibbs PA, Regine WF, Dempsey RJ, Mohiuddin M, Kryscio RJ, et al. Postoperative radiotherapy in the treatment of single metastases to the brain: a randomized trial. *JAMA.* 1998; 280: 1485-1489.
16. Tsao MN, Xu W, Wong RK, Lloyd N, Laperriere N. Whole brain radiotherapy for the treatment of newly diagnosed multiple brain metastases. *Cochrane Database Syst Rev.* 2018; 1: CD003869.
17. Heisterkamp C, Haatanen T, Schild SE, Rades D. Dose escalation in patients receiving whole-brain radiotherapy for brain metastases from colorectal cancer. *Strahlenther Onkol.* 2010; 186: 70-75.
18. Sperduto PW, Shanley R, Luo X, Andrews D, Wasik M, et al. Secondary analysis of RTOG 9508, a phase 3 randomized trial of wholebrain radiation therapy versus WBRT plus stereotactic radiosurgery in patients with 1–3 brain metastases; poststratified by the graded prognostic assessment. *Int J Radiat Oncol Biol Phys.* 2014; 90: 526-531.
19. Suteu P, Fekete Z, Todor N, Nagy V. Survival and quality of life after whole brain radiotherapy with 3D conformal boost in the treatment of brain metastases. *Med Pharm Rep.* 2019; 92: 43-51.
20. Martinage G, Geffrelet J, Stefan D. Efficacy and Tolerance of post-operative hypo-fractionated stereotactic radiotherapy in a large series of patients with brain metastases. *Front Oncol.* 2019.
21. Linskey ME, Andrews DW, Asher AL. The role of stereotactic radiosurgery in the management of patients with newly diagnosed brain metastases: a systematic review and evidence-based clinical practice guideline. *J Neurooncol.* 2010; 96: 45-68.
22. Adler JR, Cox RS, Kaplan I, Martin DP. Stereotactic radio surgical treatment of brain metastases. *J Neurosurg.* 1992; 76: 444-449.
23. Shaw E, Scott C, Souhami L. Single dose radiosurgical treatment of recurrent previously irradiated primary brain tumors and brain metastases: final report of RTOG protocol 90-05. *Int J Radiat Oncol Biol Phys.* 2000; 47: 291-298.
24. Suki D, Hatiboglu MA, Patel AJ. Comparative risk of leptomeningeal dissemination of cancer after surgery or stereotactic radiosurgery for a single supratentorial solid tumor metastasis. *Neurosurgery.* 2009; 64: 664-674.
25. Johnson MD, Avkshtol V, Baschnagel AM. Surgical resection of brain metastases and the risk of leptomeningeal recurrence in patients treated with stereotactic radiosurgery. *Int J Radiat Oncol Biol Phys.* 2016; 94: 537-543.
26. Atalar B, Modlin LA, Choi CY, Adler JR, Gibbs IC, Chang SD, et al. Risk of leptomeningeal disease in patients treated with stereotactic radiosurgery targeting the postoperative resection cavity for brain metastases. *Int J Radiat Oncol Biol Phys.* 2013; 87: 713-718.
27. Veninga T, Langendijk HA, Slotman BJ, Rutten EH, Kogel AJV, et al. Reirradiation of primary brain tumours: survival, clinical response and prognostic factors. *Radiother Oncol.* 2001; 59: 127-137.
28. Buglione M, Triggiani L, Grisanti S. Retreatment of recurrent adult medulloblastoma with radiotherapy: a case report and review of the literature. *J Med Case Reports.* 2013; 7: 64.
29. Nieder C, Grosu AL, Andratschke NH, Molls M. Proposal of human spinal cord reirradiation dose based on collection of data from 40 patients. *Int J Radiat Oncol Biol Phys.* 2005; 61: 851-855.