



# Conservative Management of Unilateral TMJ Fracture - A Case Report

Shunmugavelu K\*

Consultant dental surgeon, Department of dentistry / Oral and maxillofacial pathology and Faciomaxillary surgery, Kasturi Multispeciality hospital, Chennai, India

\*Corresponding author: Shunmugavelu K, Consultant dental surgeon, Department of dentistry / Oral and maxillofacial pathology and Faciomaxillary surgery, Kasturi Multispeciality hospital, Chennai, India; Tel: 0091-9789885622; E-mail: [drkarthiks1981@gmail.com](mailto:drkarthiks1981@gmail.com)

## Abstract

**Background:** The treatment of TMJ fracture remains a controversy in maxillofacial surgery. Despite mandibular fracture is a more commonly encountered fracture it is still a debate to approach the fracture surgical or conservative.

**Case report:** An interesting case of trauma on the left side of face with TMJ fracture reported to the clinic. Proper clinical examination and adequate investigations were done. We performed a conservative approach of TMJ fracture management on a 41 year old patient and followed up for 6 months. Patient had no signs of postoperative complications, patient was reviewed for 3 consecutive weeks and followed up after 6 months and found to be normal and healthy. This is suggestive of successful management of TMJ fracture.

**Conclusion:** To conclude conservative management cannot be an alternative to surgical management but in certain cases conservative management can be administered. Case selection criteria and severity of fracture determines the selection of treatment methods.

**Keywords:** TMJ fracture; Case report; Conservative management

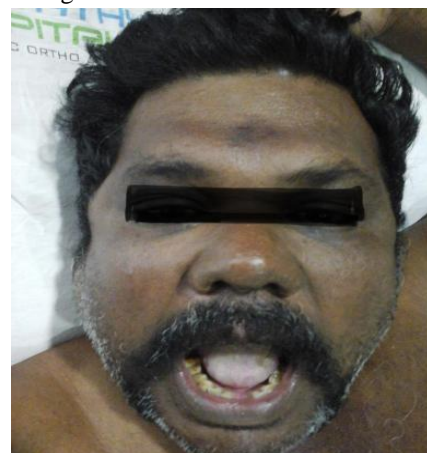## Introduction

Maxillofacial trauma constitutes nearly 10% to 40% of the mandibular fractures [1]. Historically, temporomandibular joint fractures were conservative method with various forms of immobilization or maxillomandibular fixation, with largely favourable results [2,3]. Various complications concerning trauma affecting TMJ may be seen both in surgical and conservative management [4]. Such complications include disrupted occlusal function, internal derangement of the TMJ, facial asymmetry, nerve injury, Intra alveolar and Extra-Articular Ankylosis and limited jaw movement. The choice between two treatment modalities- surgical and controversial remains highly controversial [5]. This article aims to contribute to conservative management of TMJ fractures.

## Case Report

A 41 year old male patient reported to the hospital due to trauma while working. The patient was well built and nourished, he was

conscious and well oriented to time and place. The patient had no history of vomiting. Patient written consent was obtained.



## On examination

Temporomandibular joint fracture is usually associated with complications. Immediate detection of TMJ fracture and management of the above by either conservative or surgical

Received date: 22 June 2021; Accepted date: 06 July 2021; Published date: 10 July 2021

**Citation:** Shunmugavelu K (2021). Conservative Management of Unilateral TMJ Fracture - A Case Report. SunText Rev Dental Sci 2(3): 145.

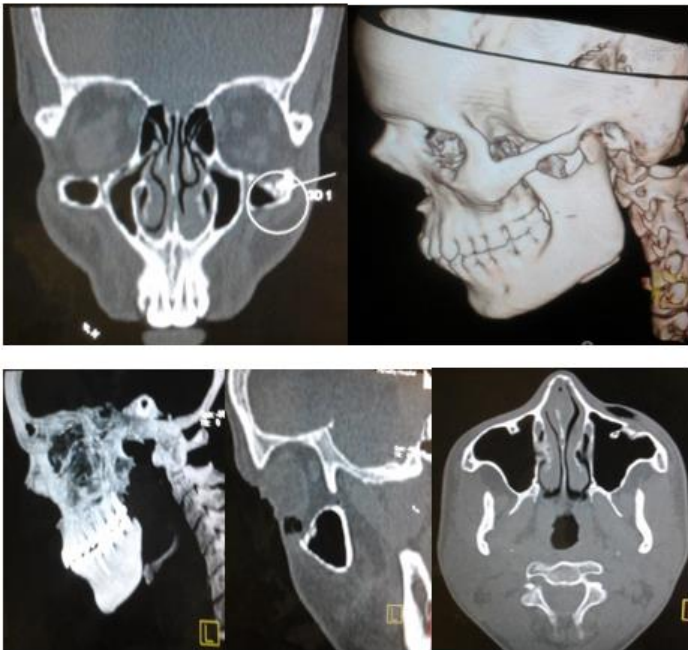
**DOI:** <https://doi.org/10.51737/2766-4996.2021.145>

**Copyright:** © 2020 Shunmugavelu K. This is an open-access article distributed under the terms of the Creative Commons Attribution License, which permits unrestricted use, distribution, and reproduction in any medium, provided the original author and source are credited.

method can have drastic consequences in limiting complications. Clinical features of TMJ fracture includes swelling, facial asymmetry, haemorrhage from ear on that side, haematoma on the involved site, ecchymosis of skin just below the mastoid process. On current visit, extra oral examination reveals left side asymmetry face, no bleeding from ears and nose was evident. Hemotympanum and hearing loss was not evident in this patient. There was a pre auricular swelling with a size 3 x 3cm, soft in consistency, tender on palpation, and the surface was warm, black blue spot suggestive of ecchymosis. Intra oral examination revealed reduced mouth opening due to blockage of coronoid process. Partially edentulousness in relation to 31, generalised attrition was evident, dental caries in relation to 16, 26 and Generalised chronic periodontitis. Patient was alright a few days after the trauma, he was conscious with pain and swelling when brought to the hospital. Facial nerve examination was done and was normal for the patient. No contributing past medical history and family history was evident.

### Provisional Diagnosis of TMJ Fracture was Given Clinically Investigations

Computed tomography was done.



**Figure 2:** A small Radiolucency on the Temporomandibular joint suggestive of fracture in the TMJ.

### Management of TMJ fractures- 2 approaches [6]

- Conservative management with inter maxillary mobilisation followed by functional therapy.

- Surgical intervention to reposition and stabilize the fragments.

### Treatment of TMJ fracture depends on various factors [7,8]

- Physical and imaging evidence of the fracture
- The extent of fracture (unilateral or bilateral)
- The level of the fracture, the degree of displacement and dislocation
- The size and position of the fractured condylar segment
- The dental malocclusion and mandibular dysfunction
- Completeness of the dentition and age of the patient.

In this case there was a unilateral swelling, with minimal degree of displacement, no alteration in dental occlusion and function.

Conservative method for managing TMJ fracture using intermaxillary fixation was done to restore the function. Conservative approach done in the patient, prevents surgical wounds and complications due to surgical management. This approach includes inter maxillary fixation for 3 weeks. And patient was recalled after 3 weeks and removed.

### Discharge Summary

The patient was admitted in the hospital in April 2020 with symptoms of swelling, post auricular ecchymosis and discharged in a week. Conservative management of the TMJ fracture was done and there were no complications and the clinical functions were retorted back to normal. Patient was fine, happy and healthy. On follow up after 6 months patient was found to be normal in function.

### Ethics

When reporting treatment measures on human subjects, the procedures were in accordance with the ethical standards of the responsible committee on human experimentation and with the Helsinki Declaration the 1975, as revised in 1983.

### Results

Within the limitations of this conservative treatment approach and investigations, there was no signs of postoperative complications like infection, hearing loss, nerve injury, malocclusion etc. This is suggestive of this approach being successful in the management of TMJ fracture.

### Discussion

TMJ fractures are associated with trauma due to direct hit to the side of the face. There is a high incidence of associated hearing loss, post auricular ecchymosis, hearing loss but facial nerve injuries and Bell's palsy are uncommon [5]. Timely management minimises complications. In our case, a 21 year old had a trauma

on the left side of his face. In most of the cases of the TMJ fractures, the complications include hearing loss, facial nerve injury, in our case, it was managed without any complications. The management of TMJ fracture in conservative method without any complications.

## Conclusion

TMJ fractures involving the condyle are 19 - 52% of the craniofacial injury. Non-surgical functional approach in unilateral TMJ fracture prevents distortion in subsequent growth. Trauma due to direct hit is the most common cause for TMJ fractures. High resolution CT and MRI were needed for the evaluation of the fracture line, structure injury and complications. Most commonly TMJ fractures are surgically managed and in our case TMJ fracture is conservatively managed without any post treatment complications. Further patient selection criteria and treatment guidelines must be formulated for better outcomes. Long term follow up and more sample size comparative study with surgical management can be done.

## Acknowledgement

The author(s) declared no potential conflict of interest with respect to authorship and/or publication of this article. No financial support was received for the authorship and/or publication of this article.

## References

1. Renapurkar SK, Strauss RA. Temporomandibular joint trauma. Atlas of the Oral and Maxillofacial Surgery Clinics. 2019; 27: 99-106.
2. Walker CJ, MacLeod SPR. Anatomy and biomechanics of condylar fractures. Atlas Oral Maxillofac Surg Clin North Am. 2017; 25: 11-16.
3. Kumar LKS, Manuel S, Kurien NM, Khalam SA, Menon V. An interesting radiological picture of post traumatic TMJ ankylosis due to sagittal condylar fracture. Int J Surg Case Rep. 2015; 12: 11-14.
4. García-Guerrero I, Ramírez JM, Gómez de Diego R, Martínez-González JM, Poblador MS, Lancho JL. Complications in the treatment of mandibular condylar fractures: Surgical versus conservative treatment. Ann Anat. 2018; 216: 60-68.
5. Vanpoecke J, Dubron K, Politis C. Condylar Fractures: An Argument for Conservative Treatment. Craniomaxillofac Trauma Reconstr. 2020; 13: 23-31.
6. Tuna EB, DüNDAR A, Çankaya AB, Gençay K. Conservative approach to unilateral condylar fracture in a growing patient: a 2.5-year follow up. The Open Dentistry J. 2012; 6: 1-4.
7. Rozeboom A. Closed treatment of mandibular condyle fractures: a systematic review.
8. Cuéllar J, Santana J, Núñez C, Villanueva J. Surgical or conservative treatment for mandibular condyle fractures. 2018; 18: 7352-7352.