



Modified Posterior Approach to the Hip Joint

Mohan Iyer K*

Senior Consultant Orthopaedic Surgeon, Bangalore, India

*Corresponding author: Mohan Iyer K, Senior Consultant Orthopaedic Surgeon, Bangalore, India; Email: kmiyer28@hotmail.com

Commentary Article

Numerous new Approaches to the Hip Joint are described since the 1990's and they are mostly based on older approaches which have been modified to a specific purpose or for a specific reason. The approach is based on the access needed, the potential for complications, and the purpose for which it is needed along with the experience of the Surgeon. The basic need is the requirement to maintain the primary blood supply to the femoral head from the medial femoral circumflex artery and its ascending branches. In Total Hip Arthroplasty, disruption of the ascending branches is of no consequence, while in Hip Resurfacing or Osteotomy, the anterior, anterolateral, lateral or medial approaches are more preferred in order to prevent osteonecrosis of the femoral head. The lateral approaches, which require osteotomy which have a significant non-union rate should also be taken into account. Overall the Surgical approaches to the hip may be broadly classified as: anterior; anterolateral; lateral; posterior; medial; lateral sub trochanteric and proximal femoral shaft Posterior Approach is normally preferred when the viability of the femoral head is not required, such as Resection Arthroplasty or insertion of a proximal femoral prostheses. However when the viability of the femoral head is necessary as in Hip Resurfacing Arthroplasty or fracture repair, the medial circumflex artery and its ascending branches must be protected. The piriformis, Obturator internus and the gemelli must be separated well away from the posterior aspect of the greater trochanter and the attachments of the Obturator externus and quadratus femoris must be preserved. Gibson was mainly responsible for the description of the posterolateral approach, which was first described and recommended by Kocker and Langenbeck, since detaching the gluteal muscles from the ilium resulting in interference with

Received date: 15 September 2021; **Accepted date:** 22 September 2021; **Published date:** 29 September 2021

Citation: Mohan Iyer K (2021). Modified Posterior Approach to the Hip Joint. SunText Rev Med Clin Res 2(3): 136.

DOI: <https://doi.org/10.51737/2766-4813.2021.036>

Copyright: © 2021 Mohan Iyer K., This is an open-access article distributed under the terms of the Creative Commons Attribution License, which permits unrestricted use, distribution, and reproduction in any medium, provided the original author and source are credited.

function of the Iliotibial tract is unnecessary, and hence post-operative recovery is rapid. Another modification of the Gibson Approach where the Hip Joint is dislocated by internal rotation, thus preserving the anterior part of the joint capsule and preventing the dislocation of the Hip joint post-operatively anteriorly was described by Marcy and Fletcher, for insertion of prostheses. The conventionally known 'Southern Approach' was developed by Austin Moore in 1957, and was called so partly because it utilized the lower part of the Kocker procedure and partly because of its origination by him in the Southern States of America. It is essentially similar to the Kocker and Gibson Approaches, with the important differences that the Gluteus Medius and Minimus being not detached from the greater trochanter and that the Hip is dislocated by medial rotation rather than by lateral rotation. A number of approaches are classified as posterior. They range from the extensive Henry approach which releases the gluteus Maximus from the iliac crest, the iliotibial band and the femoral shaft to essentially expose all of the posterior structures to the limited muscle splitting approach of Ober for drainage of the hip joint. All the Posterior Approaches have in common the posterior retraction of the gluteus maximus to enter the posterior aspect of the hip and the release or section of the short external rotator muscles to enter the hip joint. The posterior approach to the hip joint has enjoyed varying degrees of popularity among orthopedic surgeons over the past 125 years. There is general agreement that the posterior approach offers the advantages of reduced blood loss, early post-operative recovery and a reduced hospital stay. The main arguments against the use of posterior approach are an increased risk of dislocation following hip replacement surgery. In spite of well-fixed, well-

aligned components, bearing exchange has a high risk of chronic instability, which may be attributed to the resection of stabilizing soft tissue structures to gain exposure. This creates a difficult situation for the surgeon and an inexplicable one for the patient with a previously well-functioning implant. The senior author modified a technique previously described by Shaw that included an osteotomy of the posterior one third of the greater trochanter and preservation of posterior soft tissues. Thirty-five patients underwent 47 revision procedures utilizing this approach, including 16 modular component and 31 more extensive procedures. There were no dislocations or significant complications and no loss of reduction or non-union. The approach offers excellent exposure while preserving stabilizing soft tissues.

Based on the results of their study, there appears to be statistical difference between the two groups that is bipolar being better in functional aspects. The results of our study showed that the incidence of complications were lower after bipolar hemiarthroplasty. Posterior surgical approaches leave the abductors undisturbed but have been associated classically with a higher rate of postoperative instability. Over the last decade, there has been a growing interest in modifying the posterior approach in order to decrease instability rates. Although some authors have suggested that the higher instability rate associated with the posterior approach is related to poor positioning of the acetabular component, several cadaveric and clinical studies suggest that the integrity of the posterior soft-tissue structures is the critical factor for early stability after arthroplasty through a posterior approach. The posterior approach is the most common and practical of those used to expose the hip joint. Popularized by Moore, it is often called the southern approach. All posterior approaches allow easy, safe, and quick access to the joint and can be performed with only one assistant. Because they do not interfere with the abductor mechanism of the hip, they avoid the loss of abductor power in the immediate postoperative period. Posterior approaches allow excellent visualization of the femoral shaft, thus are popular for revision joint replacement surgery in cases in which the femoral component needs to be replaced. Because access to the joint involves division of the posterior capsule, if dislocation of any prosthesis occurs, it will result from flexion and internal rotation of the hip. Thus, there may be a higher dislocation rate than that from anterior approaches if the posterior approach is used in fractured neck of femur surgery in elderly bedridden patients who often lie in bed with their hips in a flexed and adducted position. The author's original paper written nearly 40 years ago presented an original technique devised to confer greater stability to the hip joint posteriorly to minimize the greater incidence of dislocation which has been reported extensively in literature [1].

Cadaveric Study

The purpose of the study with cadavers was mainly to compare, with respect to stability of the hip joint, this approach with that after the Southern Approach as described. The strength of fixation of the reattached trochanter was assessed by applying the standard dislocation manoeuvre. Three cadavers were obtained within 18 hours of death and in each both the hips were exposed. On one side the Southern approach was used and on the other side this posterior approach. A soft top uncemented Monk's prosthesis was inserted into each hip (6 in all) and closure was carried out as far as the fascial layer, which was left open to expose the reattached lateral rotators. The pelvis was fixed to a device which measured the ranges of flexion and extension, adduction and abduction and internal and external rotation of the hip being tested. Torque was applied in internal rotation when the hip was held at a fixed angle of flexion and adduction. The corresponding angle of internal rotation obtained with the torque applied was recorded when the sutures broke or the hip dislocated (Figure 1-3).

In 2 cadavers the hips exposed by this approach withstood the maximal torque applied (68 Newton metres, Nm) without any dislocation or disruption of the trochanteric fixation while in the hips replaced by the Southern approach disruption of the sutures in the lateral rotators occurred between 40 to 50 Nm, with dislocation of the prosthesis. In one cadaver the hip exposed by the Southern approach disrupted at 30 Nm with breakage of all sutures in the lateral rotators together with dislocation of the prosthesis, while the other hip exposed by this approach withstood a torque of 50 Nm after which it dislocated, leaving the trochanteric fixation and the sutures in the gluteus medius intact. Thus it was found that in all 3 cadavers the forces required to dislocate the hip and disrupt the reattachment of the lateral rotators were considerably more using this new approach than with the Southern approach, thereby confirming the greater posterior stability of the recommended modification.

Clinical Technique

The patient is placed on the sound side. The skin incision extends from just distal and lateral to the posterior superior iliac spine towards the lateral edge of the greater trochanter, with a curve in the direction of the fibres of gluteus Maximus, and extends down the shaft of the femur for about 10 cm. The gluteal fascia and the ilio-tibial tract are exposed; the deep fascia incised vertically in the lower part of the incision and the incision is curved upwards through the middle of the fibres of gluteus Maximus. The muscles now seen converging on the greater trochanter from above downwards are gluteus medius; piriformis; obturator internus, flanked by the superior and inferior gemelli; quadratus femoris, and the upper edge of the adductor magnus. All these muscles lie edge to edge, with the sciatic nerve well away from the insertion of the short lateral rotators (Figure 4).

The posterior border of the gluteus medius in the upper part and the quadrate tubercle with the lower border of the quadrate femoris in the lower part are then identified. The greater trochanter is cut through so that the detached part includes the insertion of the following structures. From below upwards these are quadratus femoris, obturator internus with the inferior and superior gaemelli, piriformis and the posterior third of the fibres of the gluteus medius. The osteotomy extends from the junction of the posterior third and anterior two-thirds of the lateral border of the greater trochanter obliquely downwards and posteriorly to the shaft of the femur just distal to the quadrate tubercle (Figure 5-20).

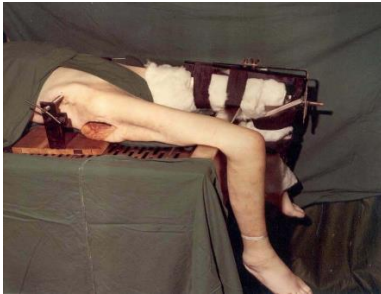

Figure 1: Device used to test stability of the hip joint showing pelvis fixed and protractors to measure the angle of flexion/extension, adduction/abduction and internal/external rotations (Courtesy: Photograph reproduced with the kind permission of Injury/Elsevier).

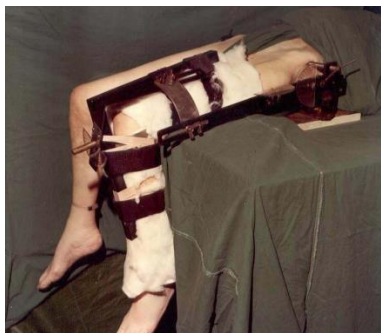

Figure 2: Device used to test stability of the hip joint showing pelvis fixed and protractors to measure the angle of flexion/extension, adduction/abduction and internal/external rotations (Courtesy: Photograph reproduced with the kind permission of Injury/Elsevier).

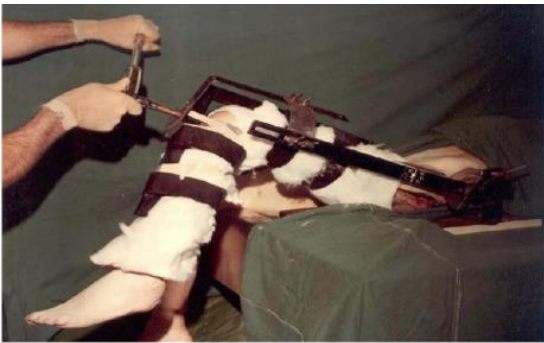

Figure 3: Internal rotation torque being applied when the hip joint was standardized to a fixed angle of flexion and adduction (Courtesy: Photograph reproduced with the kind permission of Injury/Elsevier).

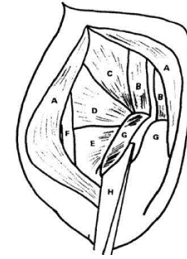


Figure 4: Line Diagram showing the osteotomy of the posterior overhanging part of the greater trochanter: (Courtesy: Line Diagram reproduced with the kind permission of Injury/Elsevier); A-Gluteusmaximus; B-Gluteus medius; C-piriformis; D-triradiatetendon; E-quadratus femoris; F-sciatic nerve; G-greater trochanter; H-osteotome.

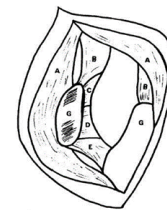


Figure 5: Line Diagram showing the osteotomy completed and the flap retracted. (Courtesy: Line Diagram reproduced with the kind permission of Injury/Elsevier); A-Gluteus maximus; B-gluteus medius; C-piriformis; D-triradiate tendon; E-Quadratus femoris; G-Greater trochanter.

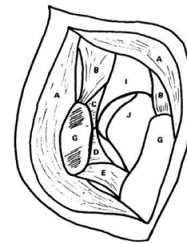

Figure 6: Line Diagram to show that the Osteotomy is completed and the flap retracted, after incising the capsule to expose the Hip Joint,(Courtesy: reproduced with the kind permission of Injury/Elsevier).

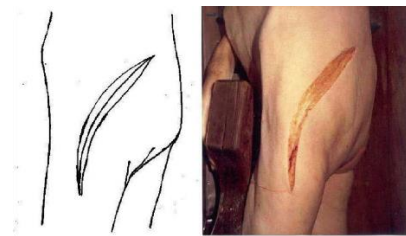

Figure 7: Skin Incision from the distal and lateral part of the trochanter to the posterior superior iliac spine with a gentle curve in the direction of the fibers of the gluteus maximus.

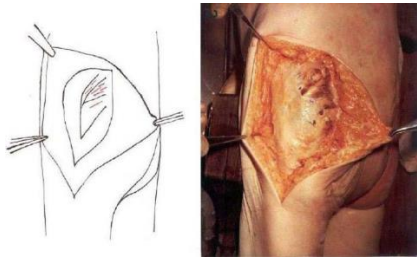


Figure 8: Incision through the gluteal fascia.

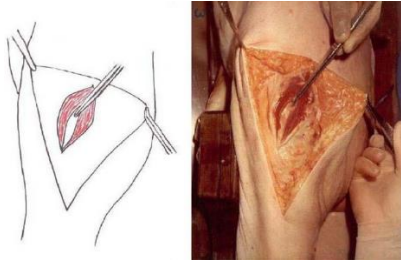


Figure 9: Incision vertically through the fibers of the gluteus maximus.

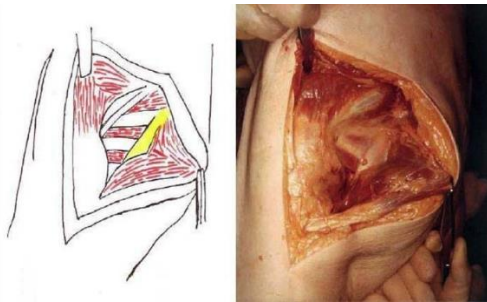


Figure 10: Exposure of the short lateral rotators.

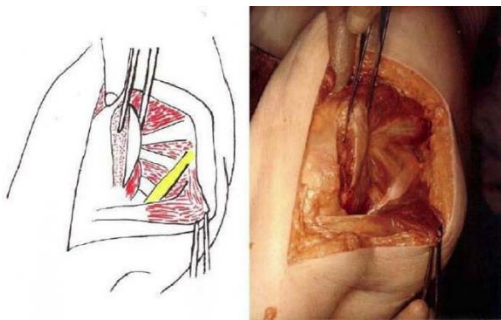


Figure 11: Posterior Trochanteric Osteotomy taking the insertion of the short lateral rotators with the sciatic nerve well away.

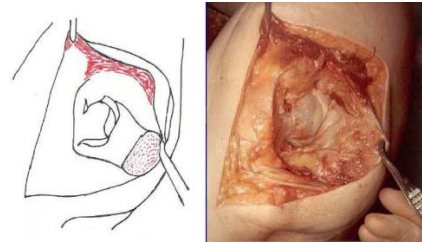


Figure 12: Exposure of the Hip Joint.

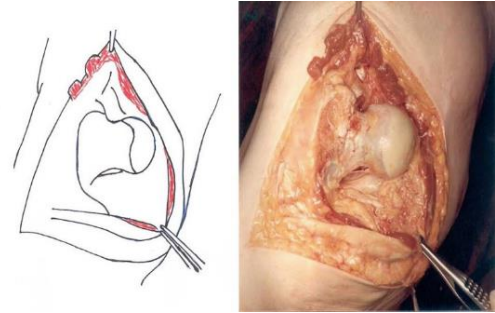


Figure 13: Dislocation of the Hip Joint.

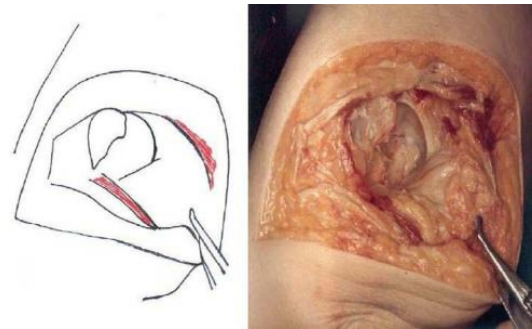


Figure 14: Resection of the head and neck of the femur.

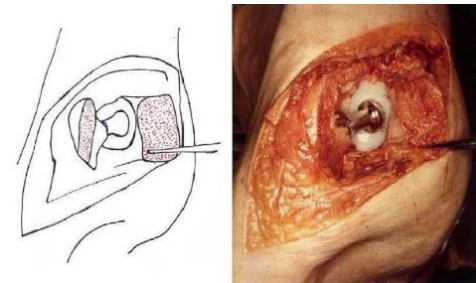


Figure 15: Insertion of the total hip Prosthesis.

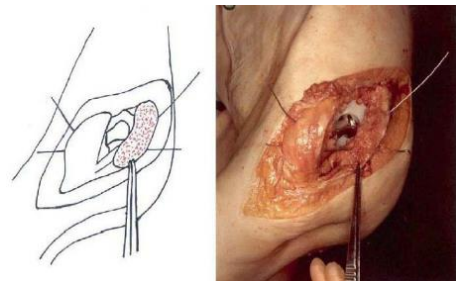


Figure 16: Wiring of the trochanteric fragment.

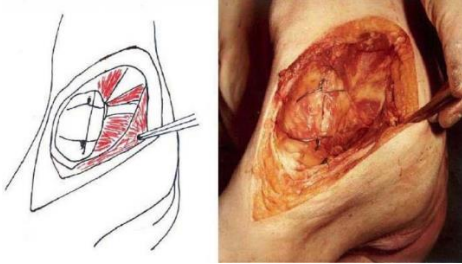


Figure 17: Reconstitution of the Hip Joint.

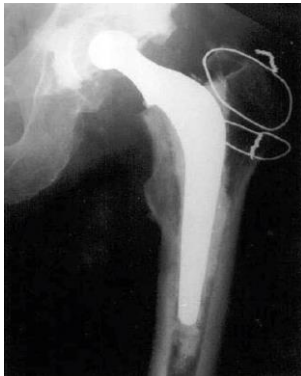

Figure 18: Radiograph of the Total Hip Prosthesis.

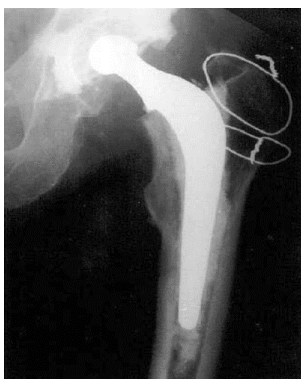

Figure 19: Radiograph of a Thompson's Prosthesis.

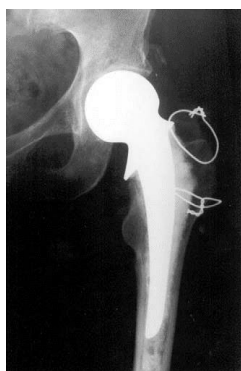

Figure 20: Radiograph of a bipolar Prosthesis.

There were no dislocations nor instability noted in the follow-up of these patients. This approach was then included in the Year

book of Orthopaedics by Mark Conventry in the year book of Orthopaedics [1]. Terry Canale of Campbell's Operative till finally by my respected teacher Mr.F.H.Beddow in the Rheumatoid Arthritis Surgical Society [2,3]. Thereafter many people like James Shaw did appreciate this approach and it in books by John J Callaghan MD, Aaron G Rosenberg MD, Harry E Rubash in The Adult Hip and Surgery of the Hip by Raymond Tonzo and finally in Minimally Invasive Total Joint [4-8]. Above all Thomas Stahelin⁸ of Zurich, Switzerland finally acknowledged and appreciated this approach. USA did acknowledge this approach by carrying out their studies with reporting their results in the Acta Orthopaedica Belgica [9-11]. The main pupose of this modification was to avoid dislocation of the Hip Joint and yet retail all the advantages of the posterior approach. In the end, my book The Hip Joint (2nd Edition) by Jenny Stanford Publishing (Singapore) which contains 32 important chapters which was released in June 2021 [12]. The basic attempts at this have been numerous Modifications to the Posterior Approach with an aim of adding more stability by numerous soft tissue enhancement procedures to the Hip Joint posteriorly.

Clinical observations made by the physiotherapist Ritika Sharma Bachelors of Physiotherapy, Delhi, India

The posterior approach is the most common surgical approach used internationally for THAs as there are more than 100 described cases in literature. There is no book written on the title (Posterior Approach to the Hip Joint) only but are in chapters in books on the Hip Joint or Approaches to the Hip Joint. This book will be published eventually by CRC Press (Taylor & Francis, UK) and it has chapterwise contributions from all over the world to include China, Japan, India, UK, USA, and Australia, France and Germany which shows the evolution and progress this approach has made since its start.

- This modification helps to increase stability of the posterior aspect of the Hip Joint by trochanteric osteotomy of the greater trochanter as noted by its cadaver's tests and hence decreases the risk of dislocation of the Hip Joint.
- There is minimal bleeding in this approach and no neurological deficit as the sciatic nerve is far away.
- It does not interfere with the abductor mechanism as it leaves the abductor mechanism intact.
- There is excellent visualization of all parts of the Hip Joint by this approach and hence useful in Heniarthroplasty, Total Hip Replacement both primary and revision where there is good visualisation of the femur also.



- Early postoperative recovery due to early mobilization with reduced length of hospital stay.

The DAA can be done on a plain table or a fracture table according to each Surgeons wishes.

The emphasis should be made on quick mobilisation rather than the word dislocation. This can be used extensively in Fracture neck of femur for Hemiarthroplasty rather than Primary or Revision Hip Replacement But with gradual understanding of the DAA, this appears to be a better substitute [13-20]. Rather than these modifications. The DAA may appear to have a very steep and difficult learning curve in the beginning, but with practice and using this DAA, it appears as an excellent substitute for the Posterior Approach to the Hip Joint. The features of DAA should be shared actively with physio/occupational therapists to avoid the necessity for the use of a low chair for sitting purposes and avoid cross the legs in bed. All HOD's in Orthopaedics should impart teaching on DAA to their students at all levels in training so that they are aware of the DAA. The 'word dislocation' has been looked as a unacceptable/inadequate/ banned as constituting a risk/ not acceptable to mention associated with mainly Posterior Approach in Surgical Approaches to the Hip Joint since over 5 decades which is extremely difficult to overcome in literature even till today. I had also described a Modified Approach to the Posterior Approach in 1981, which is well held in literature and textbooks (<https://kmohaniyer.com>) of repute even till today but I feel that we should encourage the younger generations of Orthopaedic Surgeons in the world to embrace the DAA even for the most commonly seen Fracture neck of femur initially instead to straight embarking on Primary or Revision Total Hip Arthroplasty [21]. I had done a few cases in Hemiarthroplasty only [without using a fracture table] in selective patients which is not ideal and enough to write this chapter which has a difficult learning curve and specialised surgical skills with special instruments including a special operation table for this type of Surgery. Actually Total Hip Surgery can be done as a day case as seen in my book "Hip Joint in Adults: Advances and Developments" in Chapter no.18 by Dr Med. Manfred Krieger and Dr Med. Ilan Elias, Wiesbaden, Frankfurt, Germany in 2018. Ideally this is best done by Dr John O'Donnell, Melbourne Australia with whom I had several interactions saying that he is extremely comfortable with the DAA for his Hip Replacements and that he cannot imagine changing himself for another Surgical Approach that I developed an interest in the DAA. He has also been instrumental in giving me a forward for a small book written

by me and published in 2018 by Lambert academic publishing, Germany.

References

1. Helal B. Coventry, the Year Book of Orthopaedics. British J Sports Med. 1982; 371-373.
2. Canale ST. Campbell's Operative Orthopedics. Ninth Edition. 1992; 1: 387-466.
3. Beddow FH, Tulloch C. Rheumatoid arthritis surgical society-clinical experience with the Iyer modification of the posterior approach to the hip. J Bone Joint Surg. 1990; 73: 164-165.
4. Experience with modified Posterior Approach to the Hip Joint a Technical note: Shaw JAJ Arthroplasty. 1991; 6: 11-18.
5. Rosenberg C, Rubash. The Adult Hip (Lippincott- Raven). 1998; 1: 700-718.
6. Tronzo RG. Fractures of the Hip in Adults.
7. Donnelly WJ, Kirsmer M, Hogler M, Bonutti PM, Rachbauer F, Scaffier JL, et al. Minimally unvasive total joint Arthroplasty.
8. Stahelin T, Vienne P, Hershe O. Failure of reinserted short external rotator muscles after total hip Arthroplasty. J Arthroplasty. 2002; 17: 604-607.
9. Iyer D. The Orthopaedic Enigma: A simplified classification. Internet J Orthopaedic Surgery. 2006; 3.
10. Robert CH. Personal Communication. 2010.
11. Sotelo JS, Gipple J, Berry D, Rowland C, Cofield R. Primary hip arthroplasty through a limited posterior trochanteric osteotomy. Acta Orthop Belg. 2005; 71: 548-554
12. The Hip Joint (2nd Edition). Jenny Stanford Publishing. 2021.
13. Iyer KM. Int J Surg Trans Res. 2017; 6: 59-52.
14. Bio Core. Int J Surgery Transplantation Res. 2476-2504.
15. Heutor's anterior approach to the hip joint. EC Orthopaedics. 2017; 9: 3-6.
16. The direct anterior approach to the hip joint. Ortho Res Online J. 2018.
17. Mohan IK. Direct anterior approach to the hip joint. Lambert academic publishing. 2018.
18. Donnell JO, Melbourne. Hip joint in adults: Advances and Developments: Direct Anterior Approach to the Hip Joint.
19. Hip Joint in Adults: Advances and Developments: Total hip in a day, setup and early experiences in outpatient hip surgery by Dr. med. Manfred Krieger and and Dr. med. Ilan Elias, Wiesbaden, Frankfurt, Germany.
20. Hip Preservation Techniques. The anterior approach to the hip for a minimally invasive prosthesis by Alessandro Geraci, MD, PhD; Alberto Ricciardi, MD Orthopaedic Department, San Giacomo Apostolo Hospital, Castelfranco Veneto, Italy.
21. General Principles of Orthopaedics and Truama (2nd edition by K.Mohan Iyer & Wasim Khan), The Direct Anterior approach to the Hip by Hiran Amarasekera.
22. <https://kmohaniyer.com/>